

**Correlation between Visual Field Sensitivity and  
Retinal Nerve Fiber Layer Thickness as Measured by  
Optical Coherence Tomography in Primary Open  
Angle Glaucoma Patients**

*Thesis*

*Submitted for partial fulfillment of M.Sc Degree*

*By*

**Suzan Mohammed El-Kholy**  
*(M.B.B.CH)*

**Supervised by**

**Prof. Dr. Hala Mohammed El-Mofty**  
*Professor of Ophthalmology*  
*Faculty of Medicine*  
*Cairo University*

**Prof. Dr. Soheir Mohamed Esmat**  
*Professor of Ophthalmology*  
*Faculty of Medicine*  
*Cairo University*

**Dr. Ahmad Mounir Shalaby**  
*Assistant Professor of Ophthalmology*  
*Faculty of Medicine*  
*Cairo University*

**Faculty of Medicine**  
**Cairo University**  
**2012**

## Contents

- *List of Abbreviations*
- *List of Figures*
- *List of Tables*
- *Introduction.....1*
- *Aim of work.....2*
- *Review of literature:*
  - Anatomical aspects.....3-14*
  - Evaluation techniques.....15-32*
- *Patients & methods.....33-42*
- *Results.....43-58*
- *Discussion.....59-66*
- *Summary and Conclusion.....67-68*
- *References.....69-86*
- *Arabic summary*

## *Acknowledgement*

First of all, thanks are due to *God*, the most merciful & beneficent.

I would like to express my deepest gratitude to my dear *Prof. Dr. Hala Mohammed El-Mofty, Professor of Ophthalmology, Cairo University* for her sincere support & fruitful guidance.

My profound thanks to *Prof. Dr. Soheir Mohamed Esmat, Professor of Ophthalmology, Cairo University* for her valuable advices & encouragement throughout this work.

Many thanks & respect to *Dr. Ahmad Mounir Shalaby, Assistant Professor of Ophthalmology, Cairo University* for all his efforts.

And to *my family*, whom I hold dearest to my heart, *especially my parents, my husband & my lovely daughter Nadine*, to them I owe everything I am or will be.

*Suzan El-Kholy*

## *List of Abbreviations*

AUROC	:	Area Under Receiver Operating Characteristic
BCVA	:	Best Corrected Visual Acuity
C/D ratio	:	Cup/Disc ratio
COAG	:	Chronic Open Angle Glaucoma
CRA	:	Central retinal artery
EGPS	:	European glaucoma prevention study
EMGT	:	Early Manifest Glaucoma Trial
FDT	:	Frequency Doubling Technology
GDx	:	Glaucoma Diagnosis nerve fiber analyzer
HRA	:	Heidelberg retina angiograph
HRT	:	Heidelberg Retina Tomograph
ICG	:	Indo Cyanine Green
IOP	:	Intra Ocular Pressure
LV	:	Localized Variance
MD	:	Mean Deviation
MS	:	Mean Sensitivity
OCT	:	Optical Coherence Tomography
OHTS	:	Ocular Hypertension Treatment Study
PCV	:	Peripapillary Choroidal Vessels
POAG	:	Primary Open Angle Glaucoma

PPG	:	Preperimetric glaucoma
PSD	:	Pattern Standard Deviation
PV	:	Pial Vessels
RGCs	:	Retinal Ganglion Cells
RNFL	:	Retinal Nerve Fiber Layer
ROC	:	Receiver Operating Characteristic
RPC	:	Radial Peripapillary Capillaries
SAP	:	Standard Automated Perimetry
SD	:	Standard Deviation
SLP-VCC	:	Scanning Laser Polarimetry with Variable Corneal Compensation
SPCA	:	Short Posterior Ciliary Arteries
SWAP	:	Short Wave Automated Perimetry
VA	:	Visual Acuity
VF	:	Visual Field
ZH	:	“circle” of Zinn—Haller

## List of Figures

<b>Figure number</b>	<b>Figure description</b>
<b>1</b>	Divisions of the optic nerve head
<b>2</b>	Vascular supply of the optic nerve head
<b>3</b>	Distribution of retinal nerve fibers
<b>4</b>	Fundus photo of a normal right eye
<b>5</b>	Large physiologic optic nerve head cup &Corresponding OCT image shows normal RNFL measurements
<b>6</b>	Principles of confocal scanning laser ophthalmoscopy
<b>7</b>	OPTOPOL spectral domain OCT
<b>8</b>	The normal visual field
<b>9</b>	Octopus Automated Perimetry
<b>10</b>	Disc Damage Likelihood Scale (DDLs)
<b>11</b>	Correlation between C/D ratio observed clinically and C/D ratio measured by OCT
<b>12</b>	Correlation between MD of the visual field with mean RNFL thickness measured by OCT of all tested eyes
<b>13</b>	Correlation between MS of the visual field with mean RNFL thickness measured by OCT of all tested eyes
<b>14</b>	Correlation between LV of the visual field with mean RNFL thickness measured by OCT of all tested eyes
<b>15</b>	Correlation between mean RNFL and MD for group A
<b>16</b>	Correlation between mean RNFL and MD for group B
<b>17</b>	Correlation between mean RNFL and MS for group A

<b>18</b>	Correlation between mean RNFL and MS for group B
<b>19</b>	Correlation between mean RNFL and LV for group A
<b>20</b>	Correlation between mean RNFL and LV for group B
<b>21</b>	Correlation between mean RNFL and MS for group A`
<b>22</b>	Correlation between mean RNFL and LV for group A`
<b>23</b>	Correlation between mean RNFL and MD for group A`
<b>24</b>	Correlation between mean RNFL and MD for group B`
<b>25</b>	Correlation between mean RNFL and MS for group B`
<b>26</b>	Correlation between mean RNFL and LV for group B`
<b>27</b>	Correlation between DDLS & mean RNFL thickness
<b>28</b>	Correlation between DDLS & MD
<b>29</b>	Correlation between DDLS & MS
<b>30</b>	Correlation between DDLS & LV

## *List of Tables*

- Table (1):** Gender distribution & family history for glaucoma among patients included in study.
- Table (2):** The range of age & glaucoma duration (expressed as mean, median, standard deviation, minimum & maximum) among patients.
- Table (3):** Paired differences between C/D ratio clinical – C/D ratio measured by OCT(as regards mean, SD & p-value).
- Table (4):** Correlations between RNFL and MD, MS, LV.
- Table (5):** Correlations between mean RNFL thickness and MD, MS, LV for group A and group B.
- Table (6):** Cross tabulation between mean RNFL thickness & mean sensitivity (Eyes are divided into 2 groups according to MD).
- Table (7):** Correlations between mean RNFL thickness and MD, MS, LV for group A` and group B`.
- Table (8):** Correlationsbetween mean RNFL thickness, visual field global indices (MD, MS & LV) & rim/disc ratio expressed by disc damage likelihood scale (DDLS).

## **Abstract**

**Aim:**To correlate between visual field (VF) sensitivity and retinal nerve fiber layer (RNFL) thickness, as measured by spectral domain OCT in primary open angle glaucoma patients.

**Methods:**Cross-sectional study including 32 eyes of 18 POAG patients, controlled under medical treatment. We correlated mean RNFL thickness measured by OCT with visual field global indices (MD, MS, LV). Also, correlation was done between DDLS, mean RNFL thickness and visual field global indices (MD, MS, LV).

**Results:**The correlation of RNFL and the VF parameters was not significant. Correlation was significant between DDLS & mean RNFL thickness, while it was weak between DDLS, MD, MS & LV.

**Conclusions:**Glaucoma is a disease that requires a clinical diagnosis. The correlation between detectable structural and functional damage and change in early glaucoma is at best modest. It is important to include both structural and functional examinations for assessment of glaucoma at each stage of the disease.

**Keywords:**

Glaucoma, Primary Open Angle Glaucoma, Optical Coherence Tomography (OCT), Visual Field (VF), Disc Damage Likelihood Scale (DDLS), Optic nerve head (ONH), Cup/Disc ratio (C/D ratio).

## **Introduction**

Glaucoma is a progressive degenerative neuropathy. It is one of the main causes of irreversible blindness worldwide with an important impact on quality of life.<sup>1</sup>

In the first stages, glaucoma-induced structural alterations (apoptosis of ganglion cells, nerve fiber loss, and optic disk alteration) are asymptomatic and cannot be diagnosed clinically until functional changes are detected such as early scotomas in the visual fields (VF).<sup>2</sup>

Quingley et al. demonstrated that 40–50% of axonal loss may occur before any change in visual function is detected with perimetry.<sup>2</sup> Early diagnosis of glaucoma, in the first stages, before VF alterations, permits a more accurate treatment with the goal of functional maintenance and preservation of VF with minimum damage.<sup>3,4</sup>

Optical coherence tomography (OCT) is a non-invasive, non-contact technique for imaging the layered structure of the retina.<sup>5</sup> OCT computes retinal nerve fiber layer (RNFL) thickness measurements from high-resolution cross-sectional images of the retina and is able to identify diffuse and focal RNFL defects reproducibly that occur in glaucoma<sup>6</sup>, that have been shown to correlate quantitatively with VF abnormalities.<sup>7,8</sup> Peripapillary RNFL thickness turns out to be the best marker in glaucoma assessment.<sup>9</sup>

Correlation between structural and functional test can aid in assessing the relative efficacy of the two tests in detecting glaucomatous damage and in more accurately determining the stage of the disease in an individual eye.<sup>10</sup>

**Aim of work**

To correlate between visual field (VF) sensitivity and retinal nerve fiber layer (RNFL) thickness, as measured by spectral domain OCT in primary open angle glaucoma patients.

## **Review of literature**

Glaucoma is a progressive optic neuropathy primarily damaging the ganglion cell complex and causing a gradual loss of ganglion cell axons. This pathologic alteration leads to the irreversible loss of vision, so understanding glaucomatous optic atrophy is essential in the diagnosis and management of glaucoma.

### **General Description**

The optic nerve head comprises the nerve fibers that originate in the ganglion cell layer of the retina and converge upon the nerve head from all points in the fundus. At the surface of the nerve head, these retinal ganglion cells (RGCs) axons bend acutely to exit the globe through a fenestrated scleral canal, called the lamina cribrosa. In the nerve head, the axons are grouped into approximately 1000 fascicles, or bundles, and are supported by astrocytes. There is considerable variation in the size of the optic nerve head. One study showed that, the diameter varied from 1.18 to 1.75 mm.<sup>11</sup> Other studies have revealed ranges of 0.85 to 2.43 mm in the shortest diameter and 1.21 to 2.86 mm in the longest<sup>12</sup>, or a mean of 1.88 mm vertically and 1.77 mm horizontally.<sup>13</sup> The disc area may range from 0.68 mm<sup>2</sup> to 4.42 mm<sup>2</sup>.<sup>(12)</sup> In a large, population-based study, the average disc area was 2.42 mm<sup>2</sup>.<sup>(14)</sup> In a different study, the average disc area was 2.56 mm<sup>2</sup> when measured by the Heidelberg retina tomograph (HRT) and 2.79 mm<sup>2</sup> by the analysis of disc photographs.<sup>15</sup> When optic nerve head area and neuroretinal rim area were determined in 36 radial 10- degree segments on stereophotographs, the

increase of rim area and cup area with increasing disc size differs between various disc regions. Because cup area increases more than rim area with increasing disc size, correction for disc size may be more important for segmental cup area than for segmental rim area. The rim shape with respect to the location of the smallest or broadest rim part is independent of disc size.<sup>16</sup>

Another study showed a positive correlation between the optic disc size and the thickness of the peripapillary retinal nerve fiber layer (RNFL) so that, the cross sectional area occupied by the RNF, measured by scanning laser polarimetry increased significantly with an increase in optic disc size while the ratio of inferior to total cross sectional area decreased significantly. These facts should be considered when one evaluates the RNFL thickness in patients with progressive optic neuropathies such as glaucoma.<sup>17</sup>

Studies using a confocal scanning laser tomograph showed that in healthy eyes the neuroretinal rim area and optic disc diameter have a higher correlation with the optic nerve head configuration than with age, sex, or refractive error.<sup>18</sup> The diameter and the area may vary depending on the definition of the edge of the optic disc and methods of measurement.<sup>13, 19, 20</sup>

Therefore, some authors have suggested applying various formulas to correct magnification of images when comparing disc measurements on different instruments.<sup>21,22</sup>

## Divisions of the Optic Nerve Head

The nerve head may be arbitrarily divided into four portions from anterior to posterior<sup>23</sup> (Fig. 1).

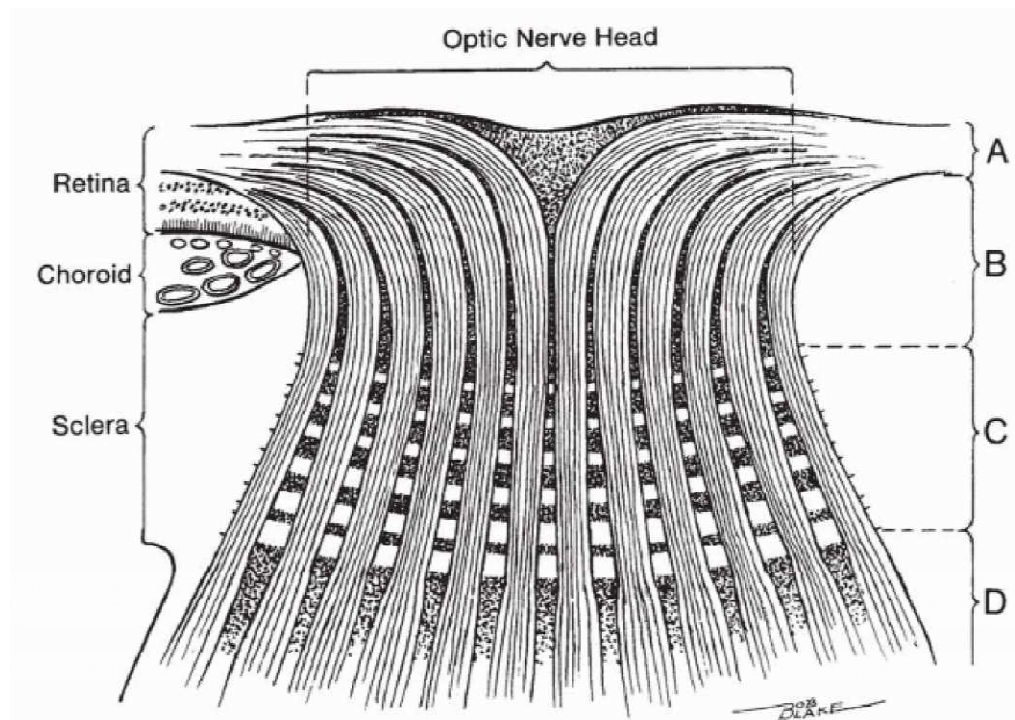


Figure (1): Divisions of the optic nerve head. A: Surface nerve fiber layer. B: Prelaminar region. C: Lamina cribrosa region. D: Retrolaminar region.<sup>24</sup>

### 1. Surface Nerve Fiber Layer

The innermost portion of the optic nerve head is composed predominantly of nerve fibers. The axonal bundles acquire progressively more interaxonal glial tissue in the intraocular portion of the nerve head as this structure is followed posteriorly.<sup>25</sup>