

Role OF Positron Emission Tomography Computed Tomography(PET CT) In Evaluation of Epilepsy

Essay submitted for partial fulfillment of master degree in
radio diagnosis

presented by

Soher Mohammed Abdelraheem

M.B.B.CH

Faculty of medicine-Ain shams university

Under supervision of

Prof.Dr.Maha Hussein Anwar Abdelsalam

Professor of Radio diagnosis

Faculty of medicine

Ain shams University

Dr.Reem Hasan Bassiouny

Assistant Professor of Radio diagnosis

Ain Shams University

Faculty of Medicine

Ain Shams University

2012

دور الانبعاث البوزتروني المقطعي مع الأشعة المقطعية في تقييم الصرع

مقالة

توطئة للحصول علي درجة الماجستير في الأشعة التشخيصية

مقدمة من

سهير محمد عبدالرحيم
(بكالوريوس الطب و الجراحة جامعة عين شمس)

اشراف

الأستاذة الدكتورة/مها حسين انور

استاذ الأشعة التشخيصية

كلية الطب — جامعة عين شمس

دكتورة/ريم حسن بسيوني

مدرس مساعد الأشعة التشخيصية

كلية الطب جامعة عين شمس

كلية الطب

جامعة عين شمس

٢٠١٢



Acknowledgment

First and foremost, I would like to thank *Allah, the most gracious beneficent and the most merciful, for achieving any work in my life.*

*I wish to express my sincere thanks and gratitude to **Prof. Dr. Maha Hussein Anwar, Professor of Radiodiagnosis, Faculty of Medicine Ain Shams University**, I am really indebted to her for her patience, unlimited support and kind encouragement during this work.*

*No words can express my deep thanks and appreciation to my **family** for their continuous support and outstanding encouragement during this work*

Soher Mohammed Abd elrahem

INTRODUCTION

EPILEPSY is one of the most neurological disorders, affecting up to 2% of the population worldwide. Studies show that patient with refractory seizures have higher morbidity and mortality rates, as well as a poorer quality of life, than those with controlled seizures. Therefore, treatment that reduces the frequency of seizures may improve patients, quality of life (**Chungss, 2010**).

A series of examinations is necessary for the diagnosis of epileptogenic zone of frontal lobe epilepsy. As neurosurgical treatments have been increasingly applied to patients who have intractable epilepsy, much knowledge on pathological changes in surgically removed brain tissues have become clearer in recent years, as well as on the neuroimaging findings which are analyzed with a variety of techniques (**Arai N et al .,2007**). The surgical outcome is related to the accuracy of epileptic foci localization and the removal of epileptogenic zone (**YU Q et al., 2010**).

Dual modality imaging is a technique in which computed tomography (CT) or magnetic resonance imaging (MRI) is combined with positron emission

(1) Introduction and aim of work

tomography (PET) or single-photon emission CT (SPECT) to acquire structural and functional images with an integrated system (**Antoch et al., 2004**). PET is unique in its ability to create "functional" images of blood flow or metabolic processes rather than the more conventional structural or anatomic images produced by x-ray examination, CT, MRI, and even SPECT (**Anderson and Price, 2000**).

Clinical studies have found PET with fluorine 18 flurodeoxyglucose (F-18 FDG) useful for making the diagnosis of a variety of neurological disorders, including seizure disorders (**Thrall and Ziessman, 2001**). Currently PET imaging in clinical neurology serves several purposes: description of path physiologic changes that are responsible for manifestation and course of a disease, and evaluation and follow-up of treatment effects. Consequently the main diagnostic issues nowadays are early diagnosis and localization of epileptogenic foci (**Jacobs and Cherry, 2001**).

Aim of work

This essay is designed to clarify the role of PET CT as a non invasive procedure in early diagnosis and localization of epileptogenic foci.

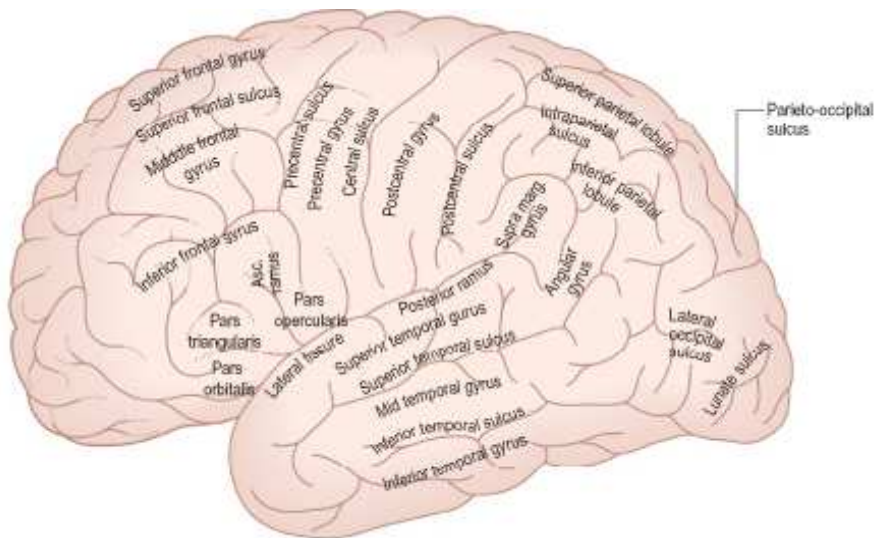
Contents

<i>(1) Introduction.....</i>	<i>1</i>
<i>(2) Neuroanatomical considerations.....</i>	<i>4</i>
<i>(3) Pathophysiology of Epilepsy.....</i>	<i>17</i>
<i>(4) Technique of PET/CT.....</i>	<i>32</i>
<i>(5) Imaging of Epilepsy.....</i>	<i>52</i>
<i>(6) Manifestations of PET/CT in Epilepsy...</i>	<i>78</i>
<i>Summary and conclusion</i>	
<i>References</i>	
<i>Arabic Summary</i>	

Neuroanatomical considerations

Anatomy of the temporal lobe:

Understanding the neuroanatomy of the temporal lobe, especially that of the amygdaloid complex and the hippocampal organization is essential for understanding and clarification of the behavioural and physiological symptoms observed in temporal lobe epilepsy (TLE) (carpenter,1978).



© Elsevier Ltd 2005. Standing: Gray's Anatomy 39e - www.graysanatomyonline.com

Figure (1-1): Lateral aspect of the left cerebral hemisphere indicating the major gyri and sulci.

The lateral surface is presented by the first two temporal convolutions and part of the third, respectively: the superior temporal gyrus of which the posterior part in

(2) Neuroanatomical considerations

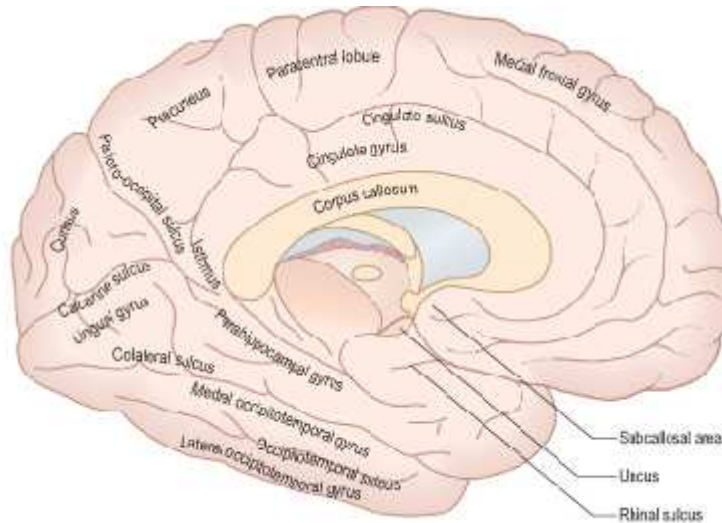
the dominant hemisphere is involved in language; the medial temporal gyrus and the inferior temporal gyrus. It is bounded above by the posterior ramus of the lateral fissure, and by the imaginary line continued backward from it; below, it is limited by the infero-lateral border of the hemisphere (**Chabardes et al., 2002**).

The superior temporal sulcus : runs from before backward across the temporal lobe, parallel but little distance below, the posterior ramus of the lateral fissure; and hence it is termed the parallel sulcus. The middle temporal sulcus takes the same direction as the superior, but is situated at a lower level, and usually subdivids into two or more parts (**Gray, 2000**). The superior temporal gyrus lies between the posterior ramus of the lateral fissure and the superior temporal sulcus, and terminates posteriorly in the gyrus supramarginalis, a transitional gyrus merging into the inferior parietal lobe. The middle temporal gyrus: is placed between the superior and middle temporal sulci, and is joined posteriorly with the gyrus angularis, another transitional gyrus, in this case between the and the parietooccipital junction. The inferior temporal gyrus is only partly visible on the lateral side and terminates

(2) Neuroanatomical considerations

posteriorly in the occipital neocortex. It extends around the infero-lateral border on to the inferior surface of the temporal lobe, where it is limited by the inferior sulcus **(Chabardes et al., 2002)**. The inferior surface is represented by the basal portion of the fourth temporal convolution or gyrus fusiformis (T4= gyrus occipito-temporalis lateralis). Posteriorly it terminates *in the* basal occipital neocortex. *Internally it* is defined by the collateral sulcus which separates it from the fifth temporal convolution (T5= gyrus para-hippocampalis) **(Chabardes et al., 2002)**. The internal surface is constituted by the hippocampal convolution, a complex gyrus including the hippocampal gyrus, the uncus and the hippocampus itself. (fig.1-2) **(Chabardes et al., 2002)**.

(2) Neuroanatomical considerations



© Elsevier Ltd 2005. Standing: Gray's Anatomy 39e - www.graysanatomyonline.com

Figure (1-2): Sagittal section of the brain, with the brain stem removed, showing the medial aspect of the left cerebral hemisphere.

The temporal lobe and the limbic system:

The limbic system is involved in the expression of emotions and the types of behavior underlying their expression. According to MacLean, this system "Is the root of what we feel, whereas the neocortex is the root of what we know". From an anatomical point of view, the limbic system (the term is derived from the Latin word *limbus* which means border) is a structural unit surrounding the diencephalon and including regions which are in functional terms very close to regions of the

(2) Neuroanatomical considerations

diencephalon and brain stem. The temporal lobe contains most of the limbic system (fig.1-3).It

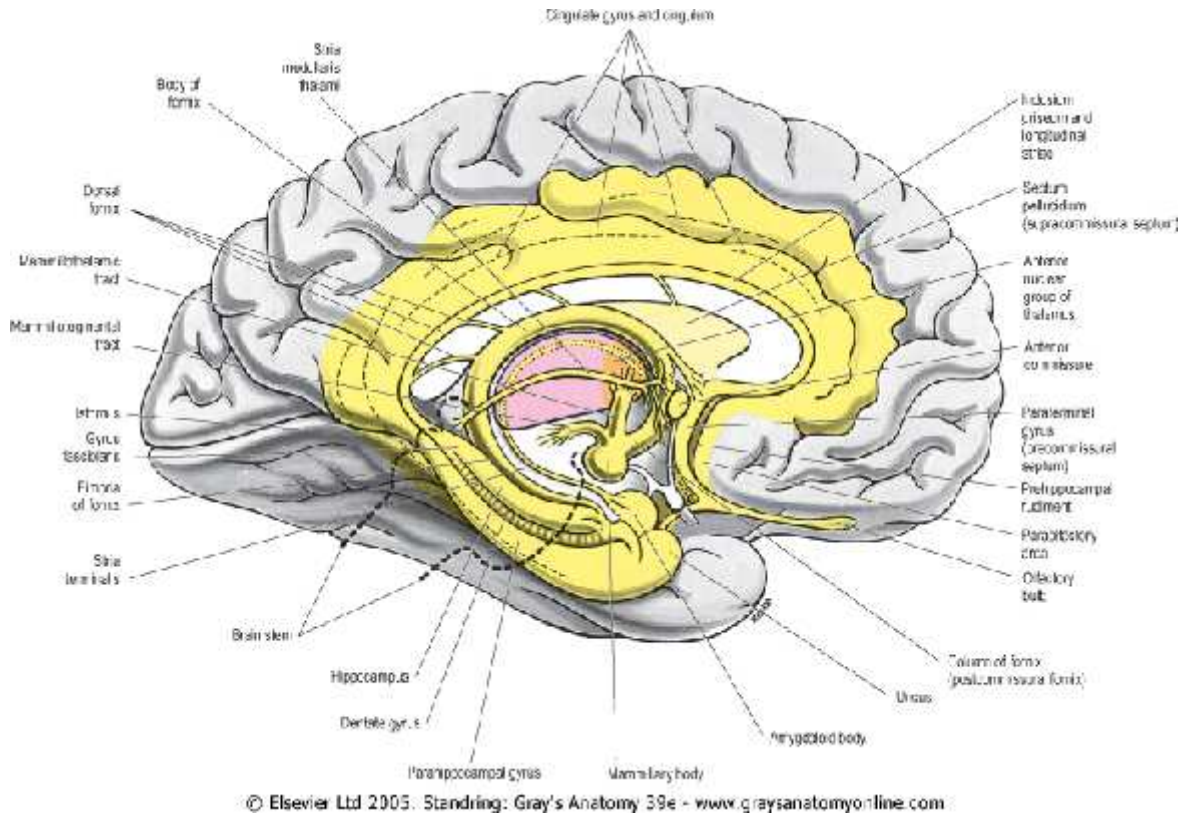


Figure (1-3): The medial aspect of the left cerebral hemisphere demonstrating some limbic structures (yellow). The anterior nuclear group of the thalamus is coloured orange and the rest of the thalamus is magenta. The approximate position of the brain stem is outlined in a heavy interrupted line.

has hemispheric components Including: the associative limbic cortex which includes the occipitofrontal region, the

(2) *Neuroanatomical considerations*

cingulum, the subiculum, the cortex of the hippocampal gyrus and the temporal pole. The hippocampal unit consisting of the hippocampus, the dentate gyrus, the amygdaloid nucleus. The septal and preoptic regions. The diencephalic components of the limbic system include the thalamus, the epithalamus and the hypothalamus (**Chabardes et al., 2002**). The *cingulate gyrus* is an arch-shaped convolution, lying in close relation to the superficial surface of the corpus callosum, from which it is separated by a slit-like fissure, the *callosal fissure*. It commences below the rostrum of the corpus callosum, curves around in front of the genu, extends along the upper surface of the body, and finally turns downward behind the splenium, where it is connected by a narrow *isthmus* with the hippocampal gyrus. The fimbria forms the crura of the fornix that continue upward deep to the splenium of the corpus callosum. As the two crura converge, a thin triangular sheet of fibers passes to the opposite side to form the commissure of the fornix. The crura merge as the body of the fornix, which continues forward along the inferior edge of the septum pellucidum and roof of the third ventricle. At the foramen of Monroe, the fornix divides into two columns which course

(2) *Neuroanatomical considerations*

inferiorly. Just superior to the anterior commissure, the columns divide into pre- and postcommissural tracts (**Gray, 2000**). The *hippocampal gyrus* is bounded above by the hippocampal fissure, and below by the anterior part of the collateral fissure. Behind, it is continuous superiorly, through the isthmus, with the cingulate gyrus and inferiorly with the lingual gyrus. Running in the substance of the cingulate and hippocampal gyri, and connecting them together, is a tract of arched fibers, named the ***cingulum***. The anterior extremity of the hippocampal gyrus is recurved in the form of a hook (***uncus***), which is separated from the apex of the temporal lobe by a slight fissure, the ***incisura temporalis***. Although superficially continuous with the hippocampal gyrus, the uncus forms morphologically a part of the rhinencephalon (**Gray, 2000**). **the hippocampal Fissure** begins immediately behind the splenium of the corpus callosum, and runs forward between the hippocampal and dentate gyri to end in the uncus. It is a complete fissure, and gives rise to the prominence of the hippocampus in the inferior cornu of the lateral ventricle (**Gray, 2000**). The **hippocampus** is a curved eminence, about 5 cm. long, consisting of two interlocking C-shaped structures which extends