


بِسْمِ اللَّهِ الرَّحْمَنِ الرَّحِيمِ





شبكة المعلومات الجامعية التوثيق الالكتروني والميكروفيلم



جامعة عين شمس

التوثيق الإلكتروني والميكروفيلم


قسم

نقسم بالله العظيم أن المادة التي تم توثيقها وتسجيلها
علي هذه الأقراص المدمجة قد أعدت دون أية تغييرات




يجب أن

تحفظ هذه الأقراص المدمجة بعيدا عن الغبار






بالرسالة صفحات لم ترد بالأصل





بعض الوثائق الأصلية تالفة



B 11291

POTENTIAL RECOVERY OF FACIAL NERVE LESIONS

Thesis

Submitted for partial Fulfillment of
The M.D. Degree in
Otorhinolaryngology

by

USAMA MASSOUD IBRAHIM
M.B.B.Ch.-M.Sc.

Supervisors

PROF. DR. AHMED ALLAM

*Professor of ENT
Banha Faculty of Medicine*

PROF. DR. MAHMOUD ABD EL- GHAFAR

*Professor of ENT
Banha Faculty of Medicine*

DR.HAMED MAHMOUD EL-SHERBIENY

*Assistant professor of ENT
Banha Faculty of Medicine*

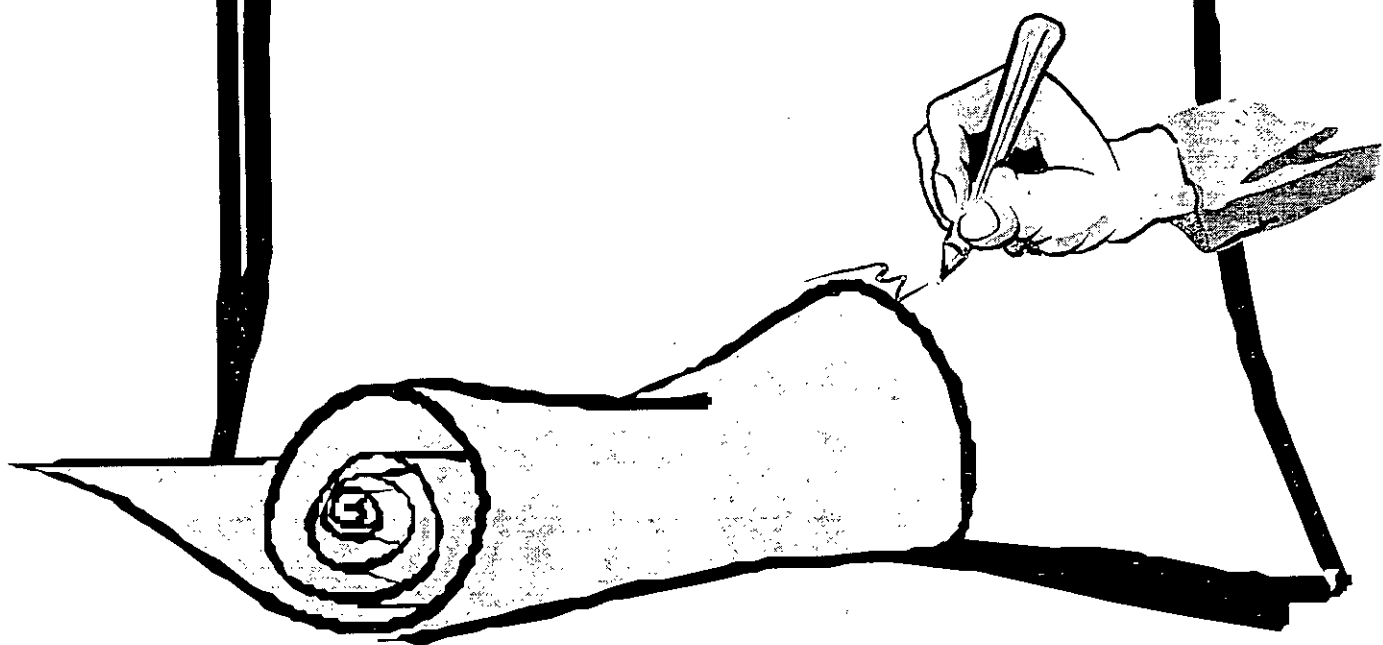
DR.ALY ABD EL-DAYEM ALY

*Assistant professor of Audiology
Faculty of Medicine
Al-Azhar University*

Banha faculty of medicine
Benha Branch-Zagazig University

2000

**To The Soul Of
Professor Doctor.
Mohamed Nabil
Abou Seif**



CONTENTS

Introduction	1
Aim of the work	2
Review of literature	3
□ Anatomy of the facial nerve.....	3
□ Surgical landmarks	30
□ Microanatomy	34
□ Neuropathophysiology	39
□ Clinical Approach	51
□ Important causes of facial injury	64
□ Facial nerve grading	73
□ Testing facial nerve function	78
□ Assessment of prognosis.....	105
Subjects and Method	110
Results	120
Discussion	148
Summary and conclusion	157
References	161
Arabic Summary	

LIST OF FIGURES

Figure	Page
Fig. (1)	4
Fig. (2)	7
Fig. (3)	11
Fig. (4)	16
Fig. (5)	17
Fig. (6)	23
Fig. (7)	27
Fig. (8)	46
Fig. (9)	50
Fig. (10)	75
Fig. (11)	79
Fig. (12)	91
Fig. (13)	111
Fig. (14)	113
Fig. (15)	116
Fig. (16)	138
Fig. (17)	139
Fig. (18)	140
Fig. (19)	141
Fig. (20)	142
Fig. (21)	143
Fig. (22)	144
Fig. (23)	145
Fig. (24)	146
Fig. (25)	147

LIST OF TABLES

Table	Page
Table. (1)	51
Table. (2)	73
Table. (3)	74
Table. (4)	76
Table. (5)	120
Table. (6)	121
Table. (7)	122
Table. (8)	122
Table. (9)	123
Table. (10)	123
Table. (11)	124
Table. (12)	124
Table. (13)	125
Table. (14)	126
Table. (15)	127
Table. (16)	128
Table. (17)	128
Table. (18)	129
Table. (19)	130
Table. (20)	130
Table. (21)	131
Table. (22)	132
Table. (23)	133
Table. (24)	134
Table. (25)	135
Table. (26)	136
Table. (27)	137

LIST OF APREVIATIONS

LMNL	Lower Motor Neuron Lesion
UMNL	Upper Motor Neuron Lesion
EEMG	Evoked Electromyography
EMG	Electromyography
NET	Nerve excitability test
MST	Maximal stimulation test
ENoG	Electroneurography
CAP	Compound action potential
TMS	Transcranial magnetic stimulation
FNLT	Facial nerve latency test

INTRODUCTION

INTRODUCTION

And Rational

The facial nerve has specific anatomical features in that it pursues a relatively long course. Facial nerve lesions which are often, exhibit a high recovery rate of facial movement (*Hosomi,1994*)

Objective evaluation of facial nerve paralysis represents a unique challenge to the clinician. Electromyography and the acoustic reflex tests have been widely used as neurophysiological tests in an assessment of facial nerve function. (*Qiu et al.,1997*)

Sunderland (1991) described five possible degrees of injury (complete, satisfactory, incomplete, week and no recovery) that a peripheral nerve fiber might undergo. This classification was dependent on the electrophysiological studies and it is more comprehensive than the classification system of *Seddon (1943)*, which described only neuroapraxia, axonotemesis and neurotmesis. (*Sunderland, 1991 and Seddon, 1943*)

Whereas tearing, salivary flow and taste tests have not been useful for diagnosis or prognosis. The prognosis for acute facial palsy can be accurately determined by serial electrical testing. These tests have been used to follow the clinical course from complete paralysis to spontaneous recovery or to the decision of intensive surgery. (*Barry and May,1997*)

The role of electrophysiological tests in the assessment of the prognosis of facial lesions in comparison to the clinical findings is still doubtful.

AIM OF THE WORK

The text "AIM OF THE WORK" is rendered in a bold, black, sans-serif font. The letters are slightly shadowed to give a three-dimensional appearance. Below the text, a series of lines radiate from a central point at the bottom, creating a fan-like or conical shape that supports the text from underneath.

AIM OF THE WORK

The aim of this study is to achieve an early prognostic pattern for facial nerve lesions using the electrophysiological studies in comparison to the clinical assessment. This may be helpful in decision making of the treatment.