

# **VASCULITIS IN RELATION TO CEREBROVASCULAR STROKE**

*An essay*

Submitted for partial fulfillment of the Master Degree in neuropsychiatry

**BY**

***Youssry Salah Shafiq***

*M.B., B.CH*

***SUPERVISED BY***

**Prof. Hany Mohamed Amin Aref**

*Professor of Neuropsychiatry*

*Faculty of Medicine-Ain Shams University*

**Dr. Hala Mahmoud El-Khawas**

*Assist. Professor of Neuropsychiatry*

*Faculty of Medicine-Ain Shams University*

**Dr. Dina Mohamed Abd-El-Gawad**

*Lecturer of Neuropsychiatry*

*Faculty of Medicine-Ain Shams University*

**Faculty of Medicine**

**Ain shams University**

**2012**

# الالتهابات الوعائية و دورها في حدوث السكتة الدماغية

رساله مقدمة من الطبيب

يسري صلاح شفيق

بكالوريوس الطب والجراحة

رسالة توطئة للحصول درجة الماجستير في الأمراض النفسية والعصبية

وهي تحت إشراف

**الأستاذ الدكتور / هانى محمد أمين عارف**

أستاذ الأمراض النفسية و العصبية

كلية الطب- جامعة عين شمس

**الدكتور هـ / هالة محمود الخواص**

أستاذ مساعد الأمراض النفسية و العصبية

كلية الطب- جامعة عين شمس

**الدكتور هـ / دينا محمد عبد الجواد**

مدرس الأمراض النفسية والعصبية

كلية الطب- جامعة عين شمس

كلية الطب

جامعة عين شمس

٢٠١٢

## **ACKNOWLEDGMENT**

*Thanks to merciful Lord for all the countless gifts you have offered me, and thanks to my family for their love and support.*

*It is a great pleasure to acknowledge my deepest thanks and gratitude to **Prof. Hany Mohamed Amin Aref**, Professor of Neuropsychiatry, Faculty of Medicine-Ain Shams University, for suggesting the topic of this essay, and his kind supervision. It is a great honour to work under his supervision.*

*I would like to express my deepest thanks and sincere appreciation to **Dr. Hala Mahmoud El-Khawas**, Assist. Professor of Neuropsychiatry, Faculty of Medicine-Ain Shams University, for her encouragement, creative and comprehensive advice until this work came to existence.*

*I would like to express my extreme sincere gratitude and appreciation to **Dr. Dina Mohamed Abd-El-Gawad**, Lecturer of Neuropsychiatry, Faculty of Medicine-Ain Shams University, for her kind endless help, generous advice and support during the study.*

**Youssry Salah Shafiq**

**2012**

# CONTENTS

<b>Subject</b>	<b>page</b>
1. List of abbreviations.....	III
2. List of figures.....	VIII
3. List of tables.....	IX
4. Introduction and aim of the work.....	1
5. Chapter (1): Classification.....	8
6. Chapter (2): Pathophysiology of Vasculitis.....	21
7. Chapter (3): Vasculitis and Stroke.....	29
Systemic Vasculitis and Stroke.....	46
Primary Vasculitis of the Nervous system and Stroke.....	108
Childhood Central Nervous system vasculitis and Stroke.....	143
Secondary vasculitis of the Nervous system and Stroke....	161
8. Discussion.....	193
9. Summary.....	205
10. References.....	226
11. Arabic summary.....	

## *List of Abbreviations*

- **AASV** : ANCA-associated vasculitis.
- **ACA** : Anterior cerebral artery.
- **ACR** : American College of Rheumatology.
- **AAV** : Antineutrophilic antibody vasculitis.
- **AIDS** : Acquired Immune Deficiency Syndrome.
- **ANCA** : Antineutrophil Cytoplasmic Autoantibodies.
- **APS** : Antiphospholipid syndrome.
- **AZA** : Azathioprine.
- **BD** : Behcet Disease.
- **BVAS** : Birmingham Vasculitis Assessment Score.
- **cANCA** : Cytoplasmic Antineutrophil Cytoplasmic Autoantibodies.
- **CHCC** : Chapel Hill Consensus Conference.
- **CMV** : Cytomegalovirus.
- **CNS** : Central Nervous System.
- **COX-2** : Cyclooxygenase-2.
- **cPAN** : Classical Polyarteritis nodosa.
- **cPACNS** : Childhood Primary Angiitis of central nervous system.
- **CK** : Creatinine kinase.
- **CMV** : Cytomegalovirus.
- **CRP** : C-Reactive Protein.
- **CSF** : Cerebrospinal fluid.
- **CSS** : Churg-Strauss Syndrome.

- **CT** : Computer-assisted tomography.
- **CTD** : Connective tissue disease.
- **CVT** : Cerebral Venous Thrombosis.
- **CYC** : Cyclophosphamide.
- **DAH** : Diffuse alveolar hemorrhage.
- **DAH** : Diffuse alveolar hemorrhage
- **DAMPs** : Damage-associated molecular patterns.
- **DC**: Dendritic cells.
- **EBMT** : European Group of Blood and Marrow Transplantation.
- **EM** : Electron microscope.
- **ELISA** : Enzyme linked immunosorbent assays.
- **ESR** : Erythrocyte sedimentation rate.
- **Fc** : Fragment crystallization.
- **GACNS** : Granulomatous Angiitis of central nervous system.
- **GC** : Glucocorticoids
- **GCA** : Giant cell arteritis.
- **HBV** : Hepatitis B virus.
- **HCV** : Hepatitis C virus.
- **HIV** : Human immunodeficiency virus.
- **HMGB1** : High-mobility group box 1.
- **HSP** : Henoch-Schonlein purpura.
- **ICA** : Internal carotid artery.
- **ICAM1**: Intercellular adhesion molecule 1.

- **Ig** : Immunoglobulin.
- **IL** : Interleukin.
- **IMPDH** : Inosine monophosphate dehydrogenase.
- **IVIg** : Intravenous immunoglobulins.
- **KD** : Kawasaki disease.
- **LMV** : Lupus Mesenteric Vasculitis.
- **MCA** : Middle cerebral artery.
- **MCLN** : Mucocutaneous Lymph Node syndrome.
- **MELAS** : Mitochondrial, Encephalomyopathy, Lactic acidosis, and Stroke syndrome.
- **MMF** : Mycophenolate mofetil.
- **MMPs** : Matrix metalloproteinases.
- **MPA** : Microscopic polyangiitis.
- **MMP-2** : Matrix metalloproteinase.
- **MPO** : Myeloperoxidase.
- **MRA** : Magnetic resonance angiography.
- **MRI** : Magnetic resonance imaging.
- **MTX** : Methotrexate.
- **NBD** : NeuroBehcet Disease.
- **NETs** : Neutrophil extracellular traps.
- **NMDA** : N-methyl-D-aspartate.
- **NOS** : Nitric oxide synthase.
- **PACNS** : Primary Angiitis of central nervous system.

- **PAH** : Pulmonary artery hypertension.
- **PAN** : Polyarteritis Nodosa.
- **pANC** : Perinuclear immunofluorescence Antineutrophil Cytoplasmic Autoantibodies.
- **PET** : Positron emission tomography.
- **PMN** : polymorphonuclear
- **PNS** : Prepheral Nervous System.
- **PR3** : proteinase 3.
- **pSS** : Primary Sjogren's syndrome.
- **PSV** : Primary Systemic Vasculitis.
- **PTU** : Propylthiouracil.
- **RAGE** : Rodent advanced glycation end product.
- **RCVS (RVCS)**: Reversible Cerebral Vasoconstrictor Syndrome.
- **ROS** : Release oxygen radicals.
- **sELAM-1** : serum Endothelial leucocyte adhesion molecule.
- **SLE** : Systemic lupus erythematosus.
- **SPECT** : Single photon emission-computed tomography.
- **SS** : Sjogren's syndrome.
- **SVcPACNS** : Small vessel childhood primary angiitis of the central nervous system.
- **TAK** : Takayasu arteritis.
- **Th1** : T-helper-type-1.

- **TIMP-1** : Tissue inhibitor of metalloproteinases
- **TLRs** : Toll-like receptors.
- **TNF** : Tumour Necrosis Factor.
- **TTE** : Transthoracic echocardiography.
- **US** : Ultrasound.
- **VCAM1** : Vascular cell adhesion molecule 1.
- **VDI** : Vasculitis Damage Index.
- **VZV** : Varicella Zoster Virus.
- **WG** : Wegener's Ganulomatosis.

## List of Figures

<i>Figure</i>	<i>Page</i>
• <i>Figure 1: Diagram depicting the predominant vascular distributions of major forms of primary systemic vasculitis.</i>	12
• <i>Figure 2: Classification algorithm.</i>	15
• <i>Figure 3: Consequence of endothelial damage.</i>	26
• <i>Figure 4: Complex interactions between peripheral inflammation, stroke-induced brain inflammation and responses of the peripheral innate and adaptive immune systems to stroke.</i>	34
• <i>Figure 5: Inflammatory mechanisms before and after stroke.</i>	35
• <i>Figure 6: Primary CNS Vasculitis.</i>	123
• <i>Figure 7: MRIs showing prominent leptomenigeal contrast enhancement</i>	125
• <i>Figure 8: MRI brain</i>	126
• <i>Figure 9: MRI brain</i>	127
• <i>Figure 10: MRI brain</i>	135
• <i>Figure 11: Childhood CNS vasculitis</i>	151

## *List of Tables*

<b>Table</b>	<b><i>Page</i></b>
• <b>Table 1:</b> Sensitivity and Specificity of the American College of Rheumatology criteria for the classification of vasculitis.	9
• <b>Table 2:</b> Definitions.	11
• <b>Table 3:</b> Secondary vasculitides: antigens presumably involved.	16
• <b>Table 4:</b> Classification of CNS Vasculitis.	18
• <b>Table 5:</b> Key terms to understand the immune response before, during and after stroke.	23
• <b>Table 6:</b> Potential mechanisms of vessel damage in selected primary vasculitis syndromes.	39
• <b>Table 7:</b> Prodromal symptoms of vasculitis.	48
• <b>Table 8:</b> Clinical features of PAN.	59
• <b>Table 9:</b> Disease activity and damage items routinely recorded using the most recent version of the Birmingham Vasculitis Activity Score.	78
• <b>Table 10:</b> Vasculitis Damage Index.	80
• <b>Table 11:</b> Lists suggestive patterns of primary systemic vasculitis, but it is certainly not exhaustive.	81
• <b>Table 12:</b> Initial investigations in systemic vasculitis.	85

• <b>Table 13:</b> Imaging modalities in the diagnostic work-up for primary systemic vasculitis.	92
• <b>Table 14:</b> The current use of plasma exchange in vasculitis.	100
• <b>Table 15:</b> The current roles of biological factors in treatment of vasculitis.	105
• <b>Table 16:</b> Clinical features of Granulomatous angiitis of the CNS.	112
• <b>Table 17:</b> Differential diagnosis of PACNS.	131
• <b>Table 18:</b> Differences between PACNS and RCVS.	134
• <b>Table 19:</b> Criteria for primary angiitis of the CNS (PACNS) and childhood PACNS.	144
• <b>Table 20:</b> Diagnostic algorithm for childhood central nervous system vasculitis.	154
• Scott and Bacon's criteria for the diagnosis of systemic rheumatoid vasculitis.	156
• <b>Table 21:</b> Treatment of Childhood CNS Vasculitis.	158
• <b>Table 22:</b> Differential diagnosis of childhood primary CNS vasculitis.	168
• <b>Table 23:</b> Diagnostic approach to nervous system vasculitides secondary to infections.	174
• <b>Table 24:</b> Classification of neuro-Behçet's disease.	

***Table 1: Sensitivity and Specificity of the American College of Rheumatology criteria for the classification of vasculitis:***

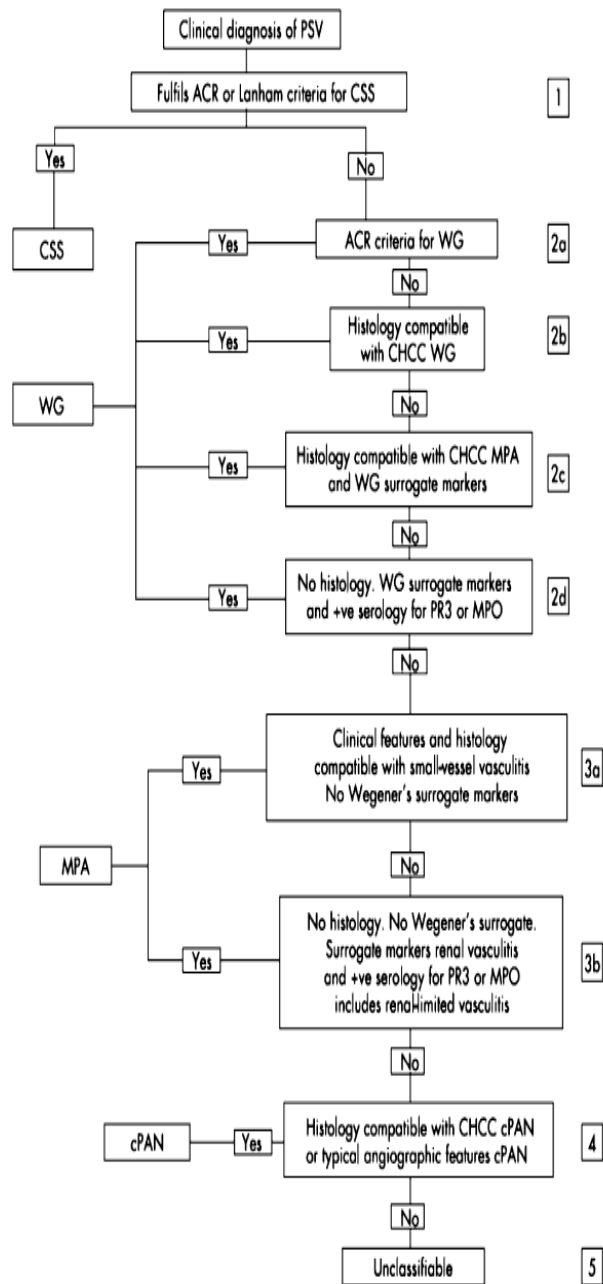
Vasculitis type	Sensitivity (%)	Specificity (%)
Polyarteritis nodosa	82.2	86.6
Churg–Strauss syndrome	85.0	99.7
Wegener’s granulomatosis	88.2	92.0
Hypersensitivity vasculitis	71.0	83.9
Henoch–Schönlein purpura	87.1	87.7
Giant cell (temporal) arteritis	93.5	91.2
Takayasu arteritis	90.5	97.8

***(Kallenberg,2008 a)***

**Table 2: Definitions:**

Name	Definition
Large vessel vasculitis	
Giant-cell (temporal) arteritis	Granulomatous arteritis of the aorta and its major branches, with a predilection for the extracranial branches of the carotid artery. Often involves the temporal artery. Usually occurs in patients more than 50 years old and is often associated with polymyalgia rheumatica
Takayasu's arteritis	Granulomatous inflammation of the aorta and its major branches. Usually occurs in patients younger than 50
Medium-sized-vessel vasculitis	
Polyarteritis nodosa	Necrotizing inflammation of medium-sized or small arteries without glomerulonephritis or vasculitis in arterioles, capillaries, or venules
Kawasaki's disease	Arteritis involving large, medium-sized, and small arteries and associated with mucocutaneous lymph node syndrome. Coronary arteries are often involved. Aorta and veins may be involved. Usually occurs in children
Small vessel vasculitis	
Wegener's granulomatosis <sup>a</sup>	Granulomatous inflammation involving the respiratory tract and necrotizing vasculitis affecting small-to-medium-sized vessels (e.g., capillaries, venules, arterioles, and arteries). Necrotizing glomerulonephritis is common
Churg-Strauss syndrome <sup>a</sup>	Eosinophil-rich and granulomatous inflammation involving the respiratory tract and necrotizing vasculitis affecting small- to medium-sized vessels and associated with asthma and eosinophilia
Microscopic polyangiitis <sup>a</sup>	Necrotizing vasculitis with few or no immune deposits affecting small vessels (capillaries, venules, or arterioles). Necrotizing arteritis involving small and medium-sized arteries may be present. Necrotizing glomerulonephritis is very common. Pulmonary capillaritis often occurs
Henoch-Schönlein purpura	Vasculitis with IgA-dominant immune deposits affecting small vessels (capillaries, venules, or arterioles). Typically involves skin, gut, and glomeruli and is associated with arthralgias or arthritis
Essential cryoglobulinemic vasculitis	Vasculitis with cryoglobulin immune deposits affecting small vessels (capillaries, venules, or arterioles) and associated with cryoglobulins in serum. Skin and glomeruli are often involved
Cutaneous leukocytoclastic angitis	Isolated cutaneous leukocytoclastic angitis without systemic vasculitis or glomerulonephritis

**(Jennette&Falk, 1997)**



**Figure 2: Classification algorithm (Watts et al, 2007).**