

Diffusion Weighted Magnetic Resonance Imaging to Monitor Treatment Response in Head and Neck Squamous Cell Carcinoma

A thesis

Submitted for Partial Fulfillment of MD Degree in Radiodiagnosis

By

Wessam Sherin Shokry

M.B.B.Ch., M.Sc. Radiodiagnosis
Faculty of Medicine, Ain Shams University

Supervised By

Dr. Randa Hussein Abdallah

Professor of Radiodiagnosis
Faculty of Medicine, Ain Sham University

Dr. Maha Khaled Abdel Ghaffar

Professor of Radiodiagnosis
Faculty of Medicine, Ain Sham University

Dr. Zeinab Mohamed Abdel Hafeez

Professor of Clinical Oncology and Nuclear Medicine
Faculty of Medicine, Ain Shams University

Dr. Ayman Mohamed Ibrahim

Assistant Professor of Radiodiagnosis
Faculty of Medicine, Ain Shams University

**Faculty of Medicine
Ain Shams University
2015**

ACKNOWLEDGEMENT

First , I thank God for completing this work, as a part of His generous help throughout our life.

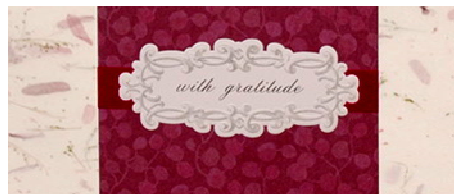*I would like to express my sincere thanks to **Prof. Dr. Randa Hussein Abdalla**, Professor of Radiodiagnosis ,Faculty of Medicine , Ain Shams University, for her endless patience , valuable remarks and guidance. This work could not have reach its goal without her support and efforts. I am very honored to have her as my supervisor. To her I owe much more than I can express.*

*My profound gratefulness and appreciation to **Prof. Dr. Maha Khaled Abdel Ghaffar**, Professor of Radiodiagnosis , Faculty of Medicine , Ain Shams University, for her sincere support and encouragement to achieve this work.*

*I wish to express my thanks to **Prof.Dr. Zeinab Abdel Hafez** , Professor of Clinical Oncology and Nuclear Medicine, Faculty of Medicine , Ain Shams University, for accepting supervision of the thesis ,for her valuable remarks and suggestions that helped me in the achievement of this work.*

*I am deeply indebted to **Prof. Dr. Ayman Mohamed Ibrahim**, Assistant Professor of Radiodiagnosis, Faculty of Medicine , Ain Shams University for his valuable remarks and generous help and advice .*

Finally , my deepest gratitude and sympathy to my family, all my professors, colleagues in Radiodiagnosis Department, who stood beside me throughout this work and especially offering me their support and encouragement during my accident and operation.



Wessam Sherin shokry

List of Contents

List of Abbreviations	II
List of Tables	IV
List of Figures	VI
Introduction	1
Aim of The Work	3
Review of Literature	4
Patients and Methods	43
Results	52
Illustrative Cases	64
Discussion	84
Summary and Conclusion	92
References	95
Arabic Summary	

List of Abbreviations

ADC	Apparent Diffusion Coefficient
ANOVA	Analysis of Variance
CR	Complete Response
CRT	Chemo Radiotherapy
DW-MRI	Diffusion Weighted Magnetic Resonance Imaging
FDG	2F-Fluoro 2 deoxy-D-glucose
FOV	Field of View
G	Glottic
HNSCC	Head and neck squamous cell carcinoma
IMRT	Intensity – Modulated Radiotherapy
LN	Lymph Nodes
M	Metastatic
N	Number
NP	Nasopharyngeal

NPV	Negative Predictive Value
PD	Progressive Disease
PET	Positron Emission Tomography
PR	Partial Response
RECIST	Response evaluation criteria in solid tumors
ROI	Region of Interest
SD	Standard Deviation
SD	Stationary Disease
SG	Supraglottic
SNR	Signal-to-Noise Ratio
STIR	Short Tau Inversion Recovery
T	Tongue
TE	Time to Echo
TI	Time to Inversion
TR	Repetition Time

List of tables

Table No.	Title	Page No.
Table (1):	TNM staging	9
Table (2):	tumor localization	45
Table (3) :	staging of patients	45
Table (4):	showing age group range of the patients.....	<u>52</u>
Table (5):	showing male to female ration among patients	<u>52</u>
Table (6):	showing number of patients with head and neck carcinoma having associated malignant lymph nodes	<u>53</u>
Table (7):	showing different primary sites of HNSCC among patients	<u>53</u>
Table (8):	showing staging of the HNSCC among patients.....	<u>54</u>
Table (9):	showing the response of patients to treatment.....	<u>56</u>
Table (10)	showing ADC values before treatment in all studied patients.	57
Table (11)	Showing relation between response to treatment among patients and the ADC value before treatment.....	58
Table (12)	Showing relation between response of treatment and the ADC value after treatment	59

List of Tables (Cont...)

Table No.	Title	Page No.
Table (13)	: showing significance of ADC after ttt versus response among the studied group	60
Table (14)	: showing relation of the change occurred in the ADC value among different types of response	<u>61</u>
Table (15)	: Showing relation of the ADC values before and after treatments and the changes occurring in the ADC value among different types of response.....	62

List of Figures

Fig. No.	Title	Page No.
Fig. (1):	Diagram showing different sites of HNSCC.....	<u>5</u>
Fig. (2):	Diagram of diffusion of water molecule	<u>15</u>
Fig. (3):	Diagram of diffusion of water molecule	<u>16</u>
Fig. (4):	Effects of diffusion gradients.	<u>17</u>
Fig. (5A,B,C):	ADC	<u>21,22</u>
Fig. (6):	MRI at the base of tongue	<u>27</u>
Fig. (7):	MRI of floor of mouth	<u>29</u>
Fig. (8):	schematic diagram shows variation in tumor apparent diffusion coefficient (ADC) with treatment.	<u>31</u>
Fig. (9):	schematic representation of the relationship between change in cellular density following an effective therapy.	<u>33</u>
Fig. (10):	MRI neck	<u>35</u>
Fig. (11):	MRI neck	<u>37</u>
Fig. (12):	PET CT	<u>41</u>
Fig. (13):	Pie chart showing site of HNSCC among patients.....	<u>54</u>

List of Figures (Cont...)

Fig. No.	Title	Page No.
Fig. (14):	Pie chart showing staging	55
Fig. (15):	Pie chart showing the response of patients to treatment.	56
Fig. (16):	Column chart showing the relation of response to treatment and ADC values before treatment	58
Fig. (17):	Column chart showing the relation of response to treatment and ADC values after treatment	59
Fig.(18):	Chart diagram showing correlation between ADC after treatment versus response	60
Fig. (19):	Column chart showing relation the change in ADC value and the response to treatment.	61
Fig. (20):	Column chart showing response of treatment and the mean ADC values before and after treatment and their changes.	63
Fig. (21):	Illustrative case 1	65
Fig. (22):	Illustrative case 2	67
Fig. (23):	Illustrative case 3	71
Fig. (24):	Illustrative case 4	74
Fig. (25):	Illustrative case 5	76

List of Figures (Cont...)

Page No.	Title	Fig. No.
<u>Fig. (26): Illustrative case 5</u>		<u>77</u>
<u>Fig. (27): Illustrative case. 6</u>		<u>79</u>
<u>Fig. (28): Illustrative case 6</u>		<u>80</u>
<u>Fig. (29): Illustrative case 7.</u>		<u>82</u>
<u>Fig. (30): Illustrative case 7</u>		<u>83</u>

Introduction

Head and Neck squamous cell carcinoma (HNSCC) represents the sixth leading cancer by incidence and there are 500000 new cases a year worldwide(*Kamangar et al., 2006*).

Multimodal treatment with radiotherapy,surgery, chemotherapy has been performed for early and advanced head and neck squamous cell carcinoma (HNSCC).Neoadjuvant induction chemotherapy has resulted in decline in the risk for distant metastasis and an upsurge in organ preservation.(*Pazdur et al.,2009*)

In general, patients responsive to induction chemotherapy also demonstrate positive responses to subsequent radiotherapy. However, given the economic burden and toxic side effects associated with induction chemotherapy in patients with HNSCC, imaging biomarkers that can evaluate treatment and survival outcomes in assessing the efficacy of induction chemotherapy are desirable (*Fury and Shah, 2010*).

An accurate pretreatment evaluation is required to determine the type and the extent of the therapy (*Yun et al., 2013*).

Moreover, although chemoradiation of HNSCC has become an integral part of patient management, it can be challenging owing to locoregional failures, if no reliable markers are available to predict the success of therapy (*Cooper et al., 2004*).

Identification of tumors that may not respond adequately to chemoradiation before beginning of therapy may allow better prognostication and counseling of patients; in some instances, it may help modification of treatment plan to include surgical debulking followed by chemoradiation in patients who may not respond well to chemoradiation alone (*Srinivasan et al., 2012*).

Aim of the work

Many multidisciplinary approaches have been applied to the treatment of head and neck squamous cell carcinoma (HNSCC). To optimize HNSCC treatment, an accurate evaluation is required to determine the type and extent of the therapy.

The present study was designed to monitor the treatment response in head and neck squamous cell carcinoma by using a recent technique, the diffusion weighted magnetic resonance imaging (DW-MRI) which has been proposed as a valuable tool in characterization of tumors in the head & neck regions.

Review of Literature

Head and neck squamous cell carcinoma Overview

Epidemiology:

Squamous cell carcinoma (SCC) is the most frequent malignant tumor of the head and neck region. Head and Neck squamous cell carcinoma (HNSCC) represents the sixth leading cancer by incidence and there are 500000 new cases a year worldwide (*Kamangar et al., 2006*).

The regions involved in such carcinomas(Fig.1) include :

1-The oral cavity as in lips, tongue, hard palate (*Williams, 2000*).

2-The Pharynx whether nasopharynx, oropharynx or hypopharynx and Tonsils (*Chaturvedi et al., 2011*).

3-The larynx (*Dechen et al., 2012*).

4-The paranasal sinuses and nasal cavity (*Mendenhall et al., 2011*).

Sometimes cancerous squamous cells can be found in the lymph nodes of the upper neck (*Mendenhall et al., 2001*).

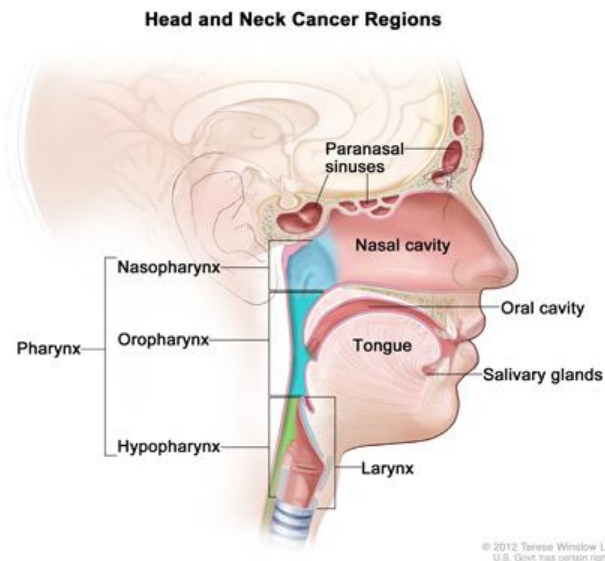


Fig. (1) .Diagram showing different sites locations for HNSCC.

Mouth and tongue cancers are more common in the Indian subcontinent, nasopharyngeal cancer in Hong Kong and Pharyngeal and laryngeal cancers are commoner in other populations (*Stenson, 2015*).

Males are affected significantly more than females with a ratio ranging from 2:1 to 15:1 depending on the site of disease. (*Mehanna et al., 2010*)