

Clinical significance of high levels of survivin and transforming growth factor beta-1 proteins in aqueous humor and serum of retinoblastoma patients



Hanan Hussein Shehata, MD,^a Azza Hassan Abou Ghalia, MD,^a Eman Khairy Elsayed, MD,^a Azza Mohamed Ahmed Said, MD,^b and Safaa Saleh Mahmoud, MD^b

PURPOSE	To evaluate the diagnostic and prognostic values of survivin and transforming growth factor beta-1 (TGF-B1) expression in aqueous humor and serum of retinoblastoma (RB) in comparison to the conventional RB marker lactate dehydrogenase (LDH) and to elucidate a possible correlation between them and the clinicopathological features of the disease.
METHODS	This prospective, comparative study included 88 newly diagnosed children with RB and 80 age-matched controls with ophthalmic conditions other than tumors prepared for intraocular surgeries. Concentrations of survivin, TGF-B1, and LDH were measured in serum and aqueous humor before and 6 months after completion of therapy.
RESULTS	High serum and aqueous humor concentrations of the three proteins were detected in RB patients before treatment compared to the control group ($P < 0.01$), with a significant reduction of serum concentrations after treatment ($P < 0.01$). For the highest sensitivity and specificity, the optimal cutoff values of serum and aqueous survivin were 12.9 pg/ml and 25.2 pg/mg, with a significant positive correlation between aqueous survivin and RB staging and presence of optic nerve infiltration ($r = 0.43$, $P = 0.04$); the best cutoff values of serum and aqueous TGF-B1, 370.7 pg/ml and 39.8 pg/mg, with a significant positive correlation between aqueous TGF-B1 and poor differentiation of the tumor ($r = 0.69$, $P = 0.001$).
CONCLUSIONS	The high sensitivity, specificity, and accuracy of serum and aqueous humor survivin and TGF-B1 proteins make them promising markers for early detection and follow-up of RB patients. (J AAPOS 2016;20:444.e1-444.e9)

Retinoblastoma (RB) is the most common intraocular cancer of childhood, with approximately 4% of all pediatric malignancies.^{1,2} Early diagnosis and recent advances in the management of RB improved the prognosis of this fatal disease.³ Nevertheless, RB remains in some particular cases difficult to diagnose,⁴ and there are still tumors that prove resistant to the administered chemotherapeutic agents.⁵

The diagnostic significance of several tumor markers in body fluids has been thoroughly investigated. An increase in the lactate dehydrogenase (LDH) activity in the aqueous

humor of RB patients was first demonstrated by Dias and colleagues.⁶ Since then, other studies have confirmed these findings.⁷⁻¹⁰ An increased LDH activity has also been reported in other nonmalignant conditions associated with intraocular cell necrosis.¹¹

Survivin is a bifunctional inhibitor of apoptosis protein (IAP) that has been implicated in regulation of mitosis and protection from apoptosis.¹² Elevated survivin levels are found in most human neoplasms,¹³ and it is used as a prognostic factor in several human neoplasms.^{13,14} Because its expression is among the most tumor-specific of all gene products, there is great interest in this protein. Manipulation of survivin regulation and expression may also lead to the development of new immunotherapy and gene therapy strategies for the treatment of cancer.¹⁵

Transforming growth factor beta (TGF-B) is the prototype for a family of multifunctional secreted peptides that controls proliferation, cellular differentiation, apoptosis, and other functions in most cells.¹⁶ TGF-B1 is overexpressed in many tumors and thought to be related to tumor transformation and progression.¹⁷ The first report of a functional union between survivin and TGF-B1 in

Author affiliations: ^aMedical Biochemistry Department, Faculty of Medicine, Ain Shams University, Cairo, Egypt; ^bOphthalmology Department, Faculty of Medicine, Ain Shams University, Cairo, Egypt

Submitted January 26, 2016.

Revision accepted July 17, 2016.

Published online September 20, 2016.

Correspondence: Azza Mohamed Ahmed Said, MD, 10th Fawzy Elmoteay Street, Heliopolis, Cairo, Egypt, 11361 (email: dr_azza_22@hotmail.com).

Copyright © 2016 American Association for Pediatric Ophthalmology and Strabismus. Published by Elsevier Inc. All rights reserved.

1091-8531/\$36.00

<http://dx.doi.org/10.1016/j.jaapos.2016.07.223>

preneoplastic and differentiated prostate carcinoma cell was published by Yang and colleagues.¹⁸

The aim of the present study was to evaluate the diagnostic and prognostic value of survivin and TGF- β 1 expression in serum and aqueous humor of RB patients in comparison to the conventional RB marker LDH in terms of sensitivity, specificity, and accuracy and to elucidate the possible correlation between them and the clinicopathological features of the disease.

Subjects and Methods

Study Population

This prospective, comparative case-control study was carried out at the Ophthalmology and the Medical Biochemistry Departments at Ain Shams University from March 2008 to November 2014. The study population comprised 88 children newly diagnosed with RB in whom enucleation was indicated at time of diagnosis in at least one eye and with no history of prior treatment and 80 age-matched controls with ophthalmic conditions other than tumors who prepared for intraocular surgeries. The parents of study participants provided informed consent. This study adhered to the tenets of the Declaration of Helsinki and was approved by the Research Ethical Committee at Faculty of Medicine, Ain Shams University.

A thorough history was taken for all children, and all children received a complete ophthalmological examination under general anesthesia with full pupillary dilatation. Fundus examination was performed for the RB group using the indirect ophthalmoscope with scleral indentation. Fundus photographs were acquired using the Genesis D (Kowa Medicals, Japan) to document clinical findings. Staging was recorded according to the international intraocular classification of RB.¹⁹ Ultrasonography was performed to determine tumor dimensions and to confirm the presence of intraocular calcification. Computed tomography of the orbits and brain was performed to detect intracranial extension and trilateral retinoblastoma. Magnetic resonance imaging was not obtained routinely but was used in cases with no visualization of the optic nerve head during clinical examination.

RB children received one or a combination of the following treatment modalities: chemoreduction with focal consolidation therapies (cryotherapy, laser thermotherapy, and brachytherapy), external beam radiotherapy, and/or enucleation.

Histopathological analysis of the enucleated eyes was performed. Ophthalmological follow-up of children to detect tumor regression and presence of resistance to treatment in the fellow eye of bilateral cases was performed every month during therapy, every 3 months during the first year after completion of therapy, then at longer intervals according to the tumor control.

Sample Collection and Storage

Venous blood samples (2 mL) were collected using disposable syringes from 88 RB children at the time of enucleation, and another sample was taken 6 months after completion of therapy (follow-up group). In addition, sera from 80 age-matched children were collected in the same fashion and used as a control at the time of analysis. Sera were obtained after centrifugation of

clotted blood samples. Samples had been divided into aliquots and stored at -20°C until laboratory analysis.

Aqueous humor samples (100–150 μL) were obtained from children in both groups under complete aseptic conditions in the operating theater. All children had general anesthesia. In the RB patients who underwent enucleation, transection of optic nerve was performed first, then the aqueous samples were collected immediately after the globe was completely removed and taken away from the surgical field to avoid risk of dissemination. Anterior chamber paracentesis was performed using 27-gauge disposable syringes with aspiration of aqueous humor using the same syringe. In the control group samples were taken at the start of the surgical procedure through one paracentesis and before instillation of any fluids or viscoelastic materials inside the eye. Aspiration was performed using a 20-gauge aspiration cannula attached to the disposable syringe. Samples were then divided into aliquots and stored at -20°C until laboratory analysis. Care was taken to avoid samples contamination with blood.

Assay Procedures

Survivin concentration was measured in serum and aqueous humor samples using an enzyme-linked immunosorbent assay (ELISA) kit from Quantikine Human Survivin Immunoassay (R and D Systems Inc, Minneapolis, MN).²⁰ TGF- β 1 concentration was also measured in serum and aqueous humor samples using enzyme-linked immunosorbent assay (ELISA) kit (TGF- β 1 ELISA kit; DRG, Springfield, NJ).²¹ Determination of LDH in serum and aqueous humor samples was carried out by the colorimetric LDH kit (SPINREACT; Centra, Santa Coloma, Spain).²² Total protein concentrations in aqueous humor samples were determined according to Bradford assay.²³

Statistical Analysis

Data were analyzed using SPSS 13 software (SPSS Inc, Chicago, IL). Continuous variables are expressed as mean and standard deviation. Description of qualitative variables was in the form of numbers and percentages. The χ^2 test and the Fisher exact test were used to compare between qualitative data. The t test was used to compare the results between two groups. The level of significance was set at $P \leq 0.05$. One-way analysis of variance (ANOVA) was used to test the significance between more than two groups. Pearson's correlation coefficient (r) was performed to test the correlation between the different variables. The best cut-off value that maximizes sensitivity and specificity and differentiates RB patients from controls was calculated by using the receiver operating characteristic (ROC) curve.

Results

The study included 88 children with newly diagnosed RB (48 females [55%]). The mean age at presentation was 17.73 ± 13.3 months (range, 2.0–60.0). The mean duration of follow up was 58.1 ± 8.93 months (range, 38.0–71.0). Unilateral RB was the diagnosis in 40 patients (46%); bilateral RB, in 48 (55%). Leucocoria was the presenting sign in 73 patients (83%); strabismus, in 8 (9%); secondary buphthalmos, in 4 patients (5%); and malignant hypopyon with

Table 1. Mean aqueous humor and serum concentrations of survivin, TGF-B1, and LDH in the RB and control groups before and after treatment

Variable	Mean \pm SD (range)		
	Control group (n = 80)	Retinoblastoma group (n = 88)	Follow-up group (n = 68)
Aqueous survivin, ^a pg/mg protein	20.2 \pm 7.7 (6.5-38.0)	31.84 \pm 12.00 (17.63- 52.70)	—
Serum survivin, ^b pg/mL	11.72 \pm 1.7 (9.38-16.7)	24.05 \pm 9.97 (2.8- 44.39)	17.2 \pm 3.92 ^c (12.93- 25.97)
Aqueous TGF-B1, pg/mg protein	23.07 \pm 11.49 (11.22-52.14)	90.79 \pm 36.28 (40.54-166.86)	—
Serum TGF-B1, pg/mL	322.18 \pm 92.9 (186.3-518.42)	429.85 \pm 60.31 (324.32- 526.46)	370.3 \pm 66.2 ^d (292.12- 477.5)
Aqueous LDH, U/L	62.18 \pm 41.64 (19.38-181.25)	591.34 \pm 222.2 (325.25-1270)	—
Serum LDH, U/L	162.12 \pm 35.63 (108.35-19.90)	371.06 \pm 124.77 (170.7-653.8)	209.95 \pm 70.78 ^e (109.6-354.55)

SD, standard deviation.

^aMean aqueous humor concentrations of survivin, TGF-B1, and LDH in RB group were significantly higher compared to control group ($P < 0.01$).

^bMean serum concentrations of survivin, TGF-B1, and LDH in the three groups were significantly higher in malignant and follow-up groups compared to control group and mean serum concentrations were reduced significantly after treatment ($P < 0.01$).

^c $P < 0.01$.

^d $P < 0.01$.

^e $P = 0.02$ (one-way ANOVA test).

proptosis, in 3 patients (3%). Positive family history was reported in 16 patients (18%); first degree consanguinity, in 12 patients (14%).

The staging of RB cases, according to the international intraocular classification of RB,¹⁹ was as follows in unilateral cases (n = 40): group D, 11 eyes (28%) and group E, 29 eyes (73%). The more advanced eyes in bilateral cases (n = 48) were staged as follows: group D, 2 eyes (4%); group E, 46 eyes (96%). The staging of the less advanced eyes in bilateral cases was as follows: group A, 16 eyes (33%); group B, 23 eyes (48%); group C, 9 eyes (19%).

Enucleation was performed for all eyes of unilateral cases and for the more advanced eye in bilateral RB; the total number of enucleated eyes was 88. The less advanced eyes in bilateral cases were treated by transpupillary thermotherapy in 8 eyes (17%), systemic chemotherapy combined with focal laser therapy in 32 eyes (67%), and systemic chemotherapy and focal laser therapy followed by external beam radiotherapy in 8 eyes (17%).

Histopathological examination of the enucleated eyes was performed and revealed the following: poorly differentiated tumor in 36 eyes (41%) and well differentiated tumor in 52 eyes (59%). Postlaminar optic nerve infiltration not involving the surgical margin was observed in 8 eyes (9%). Choroidal or scleral infiltration was not detected in specimens.

The control group consisted of 80 patients (44 males [55%]) of mean age 18.6 ± 13.2 months (range, 1.0-60.0). The indications for intraocular surgery were congenital cataract in 48 patients (60%), secondary intraocular lens implantation in 20 patients (25%), and congenital glaucoma in 12 patients (15%).

The third group was the follow-up group, which included 68 cases from the first group (44 males [65%]). These children were followed for at least 6 months after completion of therapy. The mean age was 28.7 ± 17.7 months (range, 10-72 months). There was no statistically significant difference between the study and control group as regards mean age and sex distribution ($P = 0.85$ and 0.63 , resp.).

The mean aqueous humor concentrations of survivin, TGF-B1, and LDH in RB group were significantly higher than those of the control group. Mean serum and aqueous humor concentrations of survivin, TGF-B1, and LDH in the RB group before and after treatment were significantly higher than the corresponding values in the control group. Mean serum concentrations of survivin, TGF-B1, and LDH were statistically significantly higher in the malignant and follow-up groups compared to control group. Mean serum concentration of the three proteins were reduced after treatment (Table 1).

With regard to the ROC curve and cutoff value of aqueous survivin, the area under the curve of survivin level of 0.79 and P value of 0.001 are shown in Figure 1. The best cutoff value of aqueous humor survival, yielding the highest sensitivity and specificity, was 25.2 pg/mg proteins. The area under the ROC curve of serum survivin level of 0.93 and P value of <0.0001 are shown in Figure 1. The best cutoff value of serum surviving was 12.9 pg/mL.

The area under the ROC curve of aqueous TGF-B1 level of 0.99 and P value of 0.0001 are shown in Figure 2. The best cutoff value of aqueous humor TGF-B1 was 39.8 pg/mg proteins. The area under the ROC curve of serum TGF-B1 (0.82) and P value of 0.001 are shown in Figure 2. The best cutoff value of serum TGF-B1 was 370.76 pg/mL.

The area under the ROC curve of aqueous humor LDH level (0.96) and P value of <0.0001 are shown in Figure 3. The best cutoff value of aqueous humor LDH which gave the highest sensitivity and specificity was 355.9 U/L. The area under the ROC curve of serum LDH (1.0) and ($P < 0.0001$) are shown in (Figure 3). The best cutoff value of serum LDH which gave the highest sensitivity and specificity was 235.54 U/L.

Diagnostic performance of aqueous humor and serum concentrations of survivin, TGF-B1, and LDH in RB patients and the control group was demonstrated in (Table 2).

The percentage of patients with survivin, TGF-B1, and LDH concentrations above the cutoff value were statistically significantly higher ($P \leq 0.001$) in RB group before treatment than in the other groups (Table 3).

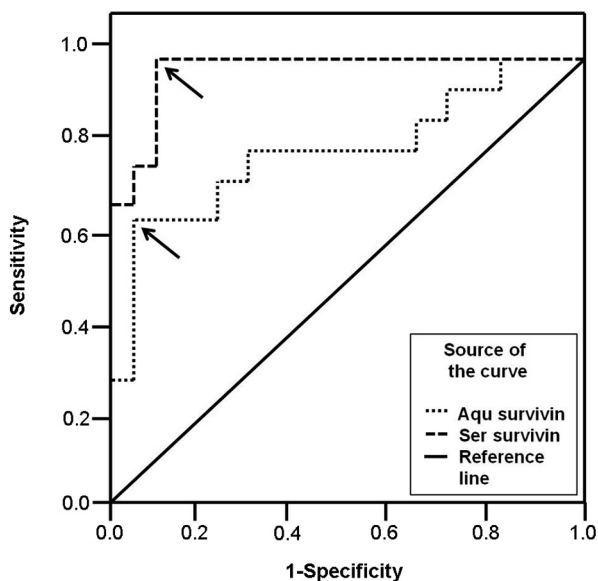


FIG 1. Receiver operating characteristic (ROC) curve showing the diagnostic performance of serum and aqueous humor survivin. The arrows indicate a cutoff value of 12.9 pg/mL of serum survivin, which yielded a sensitivity of 96.5% and specificity of 90%, and a cutoff value of 25.2 pg/mg proteins of aqueous humor survivin, which yielded a sensitivity of 62% and specificity of 100%.

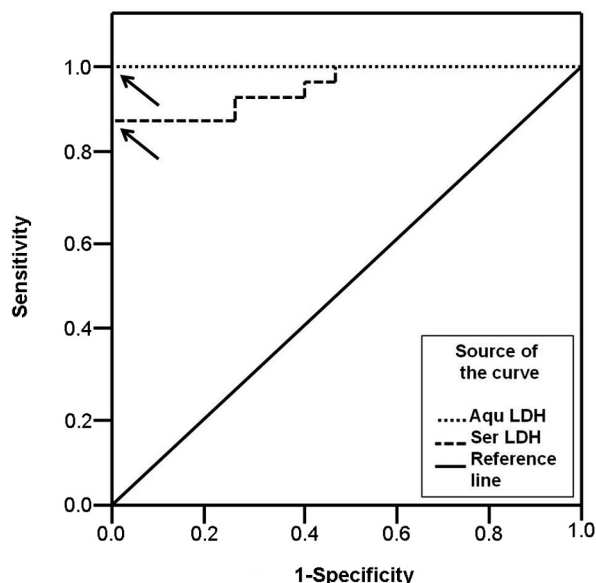


FIG 3. ROC curve showing the diagnostic performance of serum and aqueous humor lactate dehydrogenase (LDH). The arrows indicate a cutoff value of 235.54 U/L of serum LDH, which yielded a sensitivity of 88% and specificity of 100%, and a cutoff value of 355.9 U/L of aqueous humor LDH, which yielded a sensitivity of 85% and specificity of 100%.

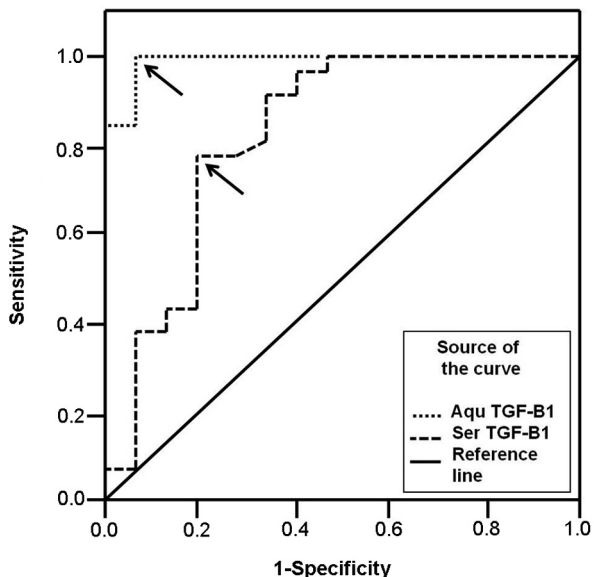


FIG 2. ROC curve showing the diagnostic performance of serum and aqueous humor TGF-B1. The arrows indicate a cutoff value of 370.76 pg/mL of serum TGF-B1, which yielded a sensitivity of 75% and specificity of 80%, and a cutoff value of 39.8 pg/mg proteins of aqueous humor TGF-B1, which yielded a sensitivity of 100% and specificity of 90%.

Comparison was done with regards to mean concentrations of the three proteins according to different clinicopathological features of the disease (Tables 4-6). A statistically significant higher concentration of aqueous

survivin in the more advanced stage of RB and in cases with optic nerve infiltration ($P = 0.04$ and 0.0002 , resp.) and a statistically significant higher concentration of aqueous TGF- B1 in undifferentiated tumors ($P = 0.0006$) were found.

Correlation between mean concentrations of serum and aqueous humor survivin, TGF- B1 and LDH and the clinicopathological features of the disease. A moderate positive significant correlation between mean aqueous humor concentration of TGF-B1 protein and poorly differentiated tumors ($r = 0.69$, $P = 0.001$) was found and also between mean aqueous humor concentration of survivin protein and staging of the disease and the presence of optic nerve infiltration ($r = 0.43$, $P = 0.04$).

Discussion

Despite extensive research efforts, the mortality rate associated with RB remains around 70%, especially in lower-income countries.²⁴ These poor outcomes are, in part, due to delayed tumor detection and lack of effective therapies targeting late-stage disease.²⁵ Also, the diagnosis of pseudo-retinoblastoma lesions is essential for proper management and to avoid unnecessary chemotherapy or enucleation.²⁶ Thus, a timely and accurate diagnosis is required for earlier treatment, which may increase the cure and survival rates,²⁷ and detecting tumor-associated antigens in serum or body fluids for the purposes of diagnosis and follow-up continues to be an important avenue of investigation.²⁸

Table 2. Diagnostic performance of aqueous humor and serum concentrations of survivin, TGF-B1, and LDH in RB patients and the control group

Variable (cutoff values)	Sensitivity (%)	Specificity (%)	PPV (%)	NPV (%)	Accuracy (%)
Aqueous survivin (25.2 pg/mg protein)	62	100	100	46	77
Serum surviving (12.9 pg/mL)	96.5	90	93	94.7	93.7
Aqueous TGF-B1 (39.8 pg/mg protein)	100	90	93	100	96
Serum TGF-B1 (370.76 pg/mL)	75	80	84	69.5	77
Aqueous LDH (355.9 U/L)	85	100	100	83	91
Serum LDH (235.54 U/L)	88	100	100	87	93.3

NPV, negative predictive value; PPV, positive predictive value.

Table 3. Percentage of patients with serum and aqueous humor concentrations of survivin, TGF-B1, and LDH proteins above the cutoff values in the different groups

Variable (cutoff values)	Group, no. (%)			P value
	Control (n = 80)	RB (n = 88)	Follow-up (n = 68)	
Aqueous survivin (25.2 pg/mg protein)	0	57 (64.7)	—	≤0.001 ^a
Serum survivin (12.9 pg/mL)	8 (10)	85 (96.5)	60 (88)	
Aqueous TGF-B1 (39.8 pg/mg protein)	8 (11)	80 (100)	—	
Serum TGF-B1 (370.76 pg/mL)	16 (20)	66 (75)	36 (53)	
Aqueous LDH (355.9 U/L)	0	67 (88)	—	
Serum LDH (235.54 U/L)	0	72 (82)	4 (5.8)	

RB, retinoblastoma.

^aPercentage of patients with serum and aqueous humor concentrations of survivin, TGF-B1 and LDH proteins above the cutoff values in RB and follow up groups was statistically higher in the RB and follow up groups compared to control group.

Table 4. Mean aqueous humor and serum concentrations of survivin protein in RB group correlated with the different clinicopathological factors

Variable (n)	Aqueous survivin (pg/mg protein), mean ± SD	P value	Serum survivin (pg/mL), mean ± SD	P value
Age, months				
1-24 (52)	33.92 ± 11.18	0.60	22.07 ± 10.64	0.85
25-48 months (12)	36.20 ± 11.20		23.34 ± 9.11	
>48 months (24)	29.70 ± 12.87		25.03 ± 10.61	
Sex				
Male (40)	33.17 ± 13.05	0.25	24.02 ± 10.22	0.65
Female (48)	29.92 ± 9.87		24.09 ± 10.20	
Family history				
Positive (16)	28.97 ± 13.86	0.60	22.55 ± 10.38	0.72
Negative (72)	32.68 ± 11.73		24.49 ± 10.13	
Tumor laterality				
Unilateral (40)	29.91 ± 12.03	0.51	23.07 ± 11.2	0.69
Bilateral (48)	33.44 ± 10.91		24.87 ± 8.31	
RB staging				
Group D (13)	25.94 ± 9.36	0.04 ^a	21.55 ± 5.36	0.32
Group E (75)	36.46 ± 11.7		25.22 ± 11.5	
Degree of differentiation				
Well differentiated (52)	33.53 ± 12.98	0.42	24.02 ± 10.0	0.98
Poorly differentiated (36)	29.40 ± 10.66		24.09 ± 10.5	
Optic nerve invasion				
Infiltrated (80)	30.25 ± 11.38	0.0002 ^a	23.30 ± 9.97	0.49
Not infiltrated (8)	47.77 ± 2.19		31.57 ± 11.8	

SD, standard deviation.

^aMean aqueous humor concentration of survivin was statistically higher in advanced stages of intraocular RB and in cases with optic nerve infiltration compared with its value in low stages of RB with no optic nerve affection ($P \leq 0.05$).

Aqueous humor of the eyes with RB has been shown to contain elevated levels of various substances.²⁹⁻³⁵ Apoptosis is a genetically controlled process that occurs both in normal and pathological conditions³⁶ and plays a

major role in the development of the central nervous system, including the retina.³⁷⁻³⁹ Evasion of apoptosis is a hallmark of human cancers that leads to cancer development, progression, and treatment resistance.⁴⁰ In

Table 5. Mean aqueous humor and serum concentrations of TGF-B1 protein in RB group in correlation to the different clinicopathological factors

Variable (Number)	Mean \pm Standard deviation		Serum TGF-B1 (pg/mL)	P value
	Aqueous TGF-B1 (pg/mg protein)	P value		
Age				
1-24 months (52)	107.21 \pm 45.32	0.17	458.16 \pm 49.11	0.45
25-48 months (12)	113.34 \pm 3.95		435.56 \pm 78.35	
>48 months (24)	78.32 \pm 33.06		417.20 \pm 59.24	
Sex				
Male (40)	80.97 \pm 33.18	0.78	432.66 \pm 72.13	0.73
Female (48)	102.80 \pm 38.14		425.78 \pm 41.40	
Family history				
Positive (16)	84.56 \pm 39.27	0.69	429.96 \pm 69.47	0.99
Negative (75)	92.87 \pm 36.43		429.81 \pm 59.73	
Tumor laterality				
Unilateral (40)	101.77 \pm 38.6	0.97	447.05 \pm 58.92	0.23
Bilateral (48)	97.71 \pm 38.1		415.51 \pm 55.36	
RB staging				
Group D (13)	89.9 \pm 38.53	0.88	421.71 \pm 64.37	0.32
Group E (75)	92.48 \pm 34.57		447.28 \pm 50.44	
Degree of differentiation				
Well differentiated (52)	68.0 \pm 24.78	0.0006 ^a	431.49 \pm 62.7	0.88
Poorly differentiated (36)	118.66 \pm 27.7		427.47 \pm 60.24	
Optic nerve invasion				
Infiltrated (80)	98.25 \pm 31.49	0.84	431.73 \pm 63.04	0.22
Not infiltrated (8)	104.74 \pm 87.85		411.01 \pm 10.73	

^aP < 0.01, mean aqueous humor concentration of TGF-B1 in undifferentiated RB was significantly higher compared to the well differentiated ones.

Table 6. Mean concentrations of LDH protein in aqueous humor and serum in RB group correlated with different clinicopathological factors, with no statistically significant difference between the subgroups (P > 0.05)

Variable (n)	Aqueous LDH (U/L), mean \pm SD	P value	Serum LDH (U/L), mean \pm SD	P value
Age				
1-24 months (52)	595.21 \pm 290.78	0.63	412.74 \pm 172.82	0.06
25-48 months (12)	493.92 \pm 142.09		482.04 \pm 137.09	
>48 months (24)	619.83 \pm 221.65		320.88 \pm 70.96	
Sex				
Male (40)	593.16 \pm 189.52	0.56	337.32 \pm 93.83	0.47
Female (48)	588.72 \pm 275.16		419.79 \pm 152.12	
Family history				
Positive (16)	542.5 \pm 91.59	0.39	353.4 \pm 119.9	0.29
Negative (72)	605.7 \pm 248.48		554.4 \pm 843.9	
Tumor laterality				
Unilateral (40)	584.63 \pm 220.2	0.90	380.38 \pm 133.35	0.76
Bilateral (48)	596.93 \pm 244.7		363.29 \pm 128.47	
RB staging				
Group D (13)	540.7 \pm 180.7	0.20	357.03 \pm 126.3	0.46
Group E (75)	699.7 \pm 276.6		401.14 \pm 125.46	
Degree of differentiation				
Well differentiated (52)	617.86 \pm 265.0	0.25	380.67 \pm 150.46	0.64
Poorly differentiated (36)	533.03 \pm 146.4		357.18 \pm 80.91	
Optic nerve invasion				
Infiltrated (80)	600.9 \pm 224.64	0.64	370.0 \pm 129.07	0.89
Not infiltrated (8)	494.9 \pm 239.92		381.64 \pm 100.9	

cancer, the balance between proliferation and apoptosis is disturbed, and defects in apoptotic pathways allow survival of cells with genetic abnormalities.⁴¹

In malignant tumors, survivin antagonizes programmed cell death, favors tumor-associated neovascularization, promotes cell proliferation, preserves cell viability, and has a strong potential of antagonizing drug and radiation induced apoptosis.⁴² Jiang and colleagues⁴³ stated that

coexistence of survivin and heat shock protein 90 probably plays an important role in cellular proliferation in RB. There has been much interest in the potential use of survivin as a tumor biochemical marker in cancer studies and in investigating the correlation between its level and the clinical course of the disease.⁴⁴⁻⁴⁹

In the present study, the mean concentration of serum survivin in the malignant group was higher compared to

the control group and reduced markedly following treatment; these results indicated indirectly that elevated serum levels of survivin were caused by the secretion of survivin into the blood from tumors. This finding agrees with the results of Wang and colleagues,⁵⁰ Hoffmann and colleagues,⁵¹ and Guney and colleagues⁵² in other types of cancer.

The first and only report about expression of survivin in aqueous humor and serum of RB patients was by Shehata and colleagues in 2010.⁵³ Similar results were reported; however, the present work included a large number of patients and investigated the level of TGF-B1 in aqueous humor and serum of the same patients in comparison to the conventional marker, LDH. We found a heretofore unrecognized significant moderate positive correlation between the stage of RB and mean aqueous humor concentration of survivin.

A significant moderate positive correlation was also found between aqueous humor concentration of survivin and RB staging and presence of optic nerve infiltration. This finding was reported also by Shehata and colleagues.⁵³ Li and colleagues⁵⁴ found the expression of survivin significantly associated with the clinical stage in nasopharyngeal carcinoma. Xiang and colleagues⁵⁵ reported that survivin expression in peripheral T cell lymphoma had no significant correlations to sex, age, clinical stage, the number of extranodal lesions, performance status, and serum level of LDH.

TGF-B is a cytokine involved in a wide variety of physiological and pathological processes. Regarding cancer, TGF-B initially contributes to maintenance of normal tissue and cellular homeostasis; nevertheless, at a particular time, TGF-B cannot suppress cancer development, and it even acts as a promoter of tumoral progression, being secreted in large quantities by neoplastic cells of several cancer types.⁵⁶ The underlying mechanisms for the elevation of TGF-B1 concentration in the course of RB are not clearly defined.

Kimchi and colleagues⁵⁷ found that RB cells lacked the three affinity-labeled proteins of 65, 95, and 300 KDa, which represent TGF-B1 receptors typically seen in human cell lines and thus distinguishing them from normal retinal cells. Loss of TGF-B1 receptors may represent one mechanism through which these cells escape from negative control and form RB. It has been suggested that RB cells are resistant to TGF-B activity due to the absence of TGF-B binding receptors in RB cells. In addition, TGF-B receptor-I may be functionally inactivated in these cell lines.⁵⁸⁻⁶⁰

Shim and colleagues⁶¹ and Chen and colleagues⁶² reported that the mean serum level of TGF-B1 was significantly decreased after treatment of cancer by surgery and/or radiation and chemotherapy. This disagrees with Sheen-Chen and colleagues⁶³ who found no significant difference in serum TGF-B1 between patients with invasive breast cancer and their control group.

TGF-B1 down-regulates survivin expression through a unique mechanism of transcriptional suppression.⁶⁴ A

novel TGF-B/Rb/survivin axis with a putative role in the functional switch of TGF-B from tumor suppressor to tumor promoter was proposed. On the other hand, Yang and colleagues¹⁸ and Ikeguchi and colleagues⁶⁵ reported that the *TGF-B* gene may play a defensive role against tumor progression by regulating survivin protein expression and by controlling occurrence of spontaneous apoptosis in hepatocellular carcinoma.

Yang and colleagues⁶⁶ and Ananiev and colleagues⁶⁷ found that expression of TGF-B1 was significantly correlated with the degree of differentiation of laryngeal squamous cell carcinoma and gastric carcinoma tissues, respectively, and this was consistent with the present study. However, Wang and colleagues⁶⁸ reported that the expression of TGF-B1 is not associated with metastasis of lymph nodes and histological types, differentiation degree, and clinical stage of ovarian carcinoma.

Dias and colleagues,⁶ Kaback and Romano,⁹ and Rohatgi and colleagues⁶⁹ reported that LDH activity in aqueous humor has a diagnostic value in RB. Some studies^{11,70,71} reported high levels of aqueous humor LDH in benign ocular conditions other than RB that were comparable to the sensitivity and specificity of aqueous humor and serum LDH in the present work. Piro and colleagues⁷² reported that only the presence of tumor in the anterior chamber correlated significantly with the aqueous humor LDH level. Dayal and colleagues⁷³ found no correlation other than with disease stage, noting that the LDH levels in the aqueous humor was significantly higher in late stages than early ones.

In conclusion, the data presented here shows that both survivin and TGF-B1 were significantly higher in RB patients in aqueous humor and serum samples than the corresponding control group. Their levels in sera markedly reduced following therapy. The high sensitivity, specificity, and accuracy of serum and aqueous humor survivin and TGF-B1 proteins make them promising markers for early detection and follow up of RB patients. Nevertheless, it remains to be determined whether there is an association between the expression and function of survivin and TGF-B1 that could help in clarifying their role in RB pathogenesis, and then they can be described as targets for RB therapy.

References

1. Shields JA, Shields CL. Management and prognosis of retinoblastoma. In: *Intraocular Tumors: A Text and Atlas*. Philadelphia: WB Saunders; 1992.
2. Shields JA, Shields CL. Retinoblastoma. In: Shields JA, Shields CL, eds. *Atlas of Intraocular Tumors*. Philadelphia: Lippincott Williams & Wilkins; 1999.
3. Heidary G, Kazlas M. Pediatric ophthalmology. In: Pavan-Langston D, ed. *Manual of Ocular Diagnosis and Therapy*. 6th ed. Philadelphia: Wolters Kluwer Health/Lippincott Williams and Wilkins; 2008:293-336.
4. Sebai L, Bouguila H, Marrakchi S, et al. Role of lactate dehydrogenase (LDH) level in the aqueous humor in the diagnosis of retinoblastoma (RB). *Tunis Med* 1999;77:651-4.

5. Shields CL, Honavar SG, Shields JA, Demirci H, Meadows AT, Naduvilath TJ. Factors predictive of recurrence of retinal tumors, vitreous seeds, and subretinal seeds following chemoreduction for retinoblastoma. *Arch Ophthalmol* 2002;120:460-64.
6. Dias PL, Shanmuganathan SS, Rajaratnam M. Lactate dehydrogenase activity of aqueous humor in retinoblastoma. *Br J Ophthalmol* 1971;5:130-32.
7. Kaneko A, Suzuki H. Lactic acid dehydrogenase activity and isozyme in the retinoblastoma. *Nippon Ganka Gakkai Zasshi* 1972;76:672-5.
8. Swartz M, Herbst RW, Goldberg MF. Aqueous humor lactic acid dehydrogenase in retinoblastoma. *Am J Ophthalmol* 1974;78:612-17.
9. Kabak J, Romano PE. Aqueous humor lactic dehydrogenase isoenzymes in retinoblastoma. *Br J Ophthalmol* 1975;59:268-9.
10. Felberg NT, McFall R, Shields JA. Aqueous humor enzyme patterns in retinoblastoma. *Invest Ophthalmol Vis Sci* 1977;16:1039-46.
11. Stone RA, Krupin T. Elevated lactic acid dehydrogenase in aqueous humor in an eye without retinoblastoma. *Am J Ophthalmol* 1976;82:94-6.
12. Andersen MH, Svane IM, Becker JC, Straten P. The universal character of the tumor-associated antigen survivin. *Clin Cancer Res* 2007;13:5991-4.
13. Rohayem J, Diestelkoetter P, Weigle B, et al. Antibody response to the tumor-associated inhibitor of apoptosis protein survivin in cancer patients. *Cancer Res* 2000;60:1815-17.
14. Johnson ME, Howerth EW. Survivin: a bifunctional inhibitor of apoptosis protein. *Vet Pathol* 2004;41:599-607.
15. Ambrosini G, Adida C, Altieri DC. A novel anti-apoptosis gene, survivin, expressed in cancer and lymphoma. *Nat Med* 1997;3:917-21.
16. Hill JJ, Tremblay TL, Cantin C, O'Connor-McCourt M, Kelly JF, Lenferink AE. Glycoproteomic analysis of two mouse mammary cell lines during transforming growth factor (TGF)-beta induced epithelial to mesenchymal transition. *Proteome Sci* 2009;7:2.
17. Markowitz S, Wang J, Myeroff L, et al. Inactivation of the type II TGF-beta receptor in colon cancer cells with microsatellite instability. *Science* 1995;268:1336-8.
18. Yang J, Song K, Tracy L, Krebs TL, Jackson MW, Danielpour D. Rb/E2f4 and smad2/3 link survivin to TGF-B-induced apoptosis and tumor progression. *Oncogene* 2008;27:5326-38.
19. Murphree AL. Intraocular retinoblastoma: the case for a new group classification. *Ophthalmol Clin N Am* 2005;18:41-53.
20. Chantalat L, Skoufias DA, Kleman JP, Jung B, Dideberg O, Margolis RL. Crystal structure of human survivin reveals a bow-tie shaped dimer with two unusual alpha-helical extensions. *Mol Cell* 2000;6:183-9.
21. Lawrence DA. Transforming growth factor-beta: an overview. *Kidney Int Suppl* 1995;49:S19-23.
22. Babson AL, Babson SR. Kinetic Colorimetric Measurement of serum lactate dehydrogenase activity. *Clin Chem* 1973;19:766-9.
23. Bradford MM. A rapid and sensitive method for the quantitation of microgram quantities of protein utilizing the principle of protein-dye binding. *Anal Biochem* 1976;72:248-54.
24. Dimaras H, Kimani K, Dimba EA, et al. Retinoblastoma. *Lancet* 2012;379:1436-46.
25. Shields CL, Fulco EM, Arias JD, et al. Retinoblastoma frontiers with intravenous, intra-arterial, periocular, and intravitreal chemotherapy. *Eye (Lond)* 2013;27:253-64.
26. Ghassemi F, Bazvand F, Makateb A. Lesions simulating retinoblastoma at a Tertiary Care Center. *J Ophthalmic Vis Res* 2015;10:316-19.
27. Liu SS, Wang YS, Sun YF, et al. Plasma microRNA-320, microRNA-let-7e and microRNA-21 as novel potential biomarkers for the detection of retinoblastoma. *Biomed Rep* 2014;2:424-8.
28. Freedman SO. Antigens in tumours. In: Symington T, Carter RL, eds. *Scientific Foundations of Oncology*. London: Heinemann; 1976:509-11.
29. Das A, Roy IS, Maitra TK, Kanjilal A. Significance of carcinoembryonic antigen in retinoblastoma. *Br J Ophthalmol* 1984;68:252-4.
30. Abramson DH, Senft SH, Servodidio CA, Ellsworth RM, Gamache PH. Retinoblastoma aqueous humor: aromatic amino acids. *Ophthalmic Paediatr Genet* 1993;14:127-30.
31. Abramson DH, Piro PA, Decresce R, Ellsworth RM, Kitchin D. Catecholamine metabolites in the aqueous of retinoblastoma. *J Pediatr Ophthalmol Strabismus* 1978;15:77-8.
32. Abramson DH, Greenfield DJ, Ellsworth RM, et al. Neuron specific enolase and retinoblastoma. *Retina* 1989;9:148-52.
33. Mendelsohn ME, Abramson DH, Senft S, Servodidio RN, Gamache EH. Uric acid in the aqueous humor and tears of retinoblastoma patients. *J AAPOS* 1998;2:369-71.
34. Mirakholi M, Mahmoudi T, Heidari M. MicroRNAs horizon in retinoblastoma. *Acta Med Iran* 2013;51:823-9.
35. Garcia JR, Gombos DS, Prospero CM, Ganapathy A, Penland RL, Chévez-Barrios P. Expression of angiogenic factors in invasive retinoblastoma tumors is associated with increase in tumor cells expressing stem cell marker Sox2. *Arch Pathol Lab Med* 2015;139:1531-8.
36. White E. Life, death, and the pursuit of apoptosis. *Genes Dev* 1996;10:1-15.
37. Bozanic D, Tafra R, Saraga-Babic M. Role of apoptosis and mitosis during human eye development. *Eur J Cell Biol* 2003;82:421-9.
38. Georges P, Madigan MC, Provis JM. Apoptosis during development of the human retina: relationship to foveal development and retinal synaptogenesis. *J Comp Neurol* 1999;413:198-208.
39. Cellerino A, Bähr M, Isenmann S. Apoptosis in the developing visual system. *Cell Tissue Res* 2000;301:53-69.
40. Hanahan D, Weinberg RA. The hallmarks of cancer. *Cell* 2000;100:57-70.
41. Afford S, Randhawa S. Apoptosis. *J Clin Pathol Mol Pathol* 2000;53:55-63.
42. Lechler P, Renkawitz T, Campean V, et al. The antiapoptotic gene survivin is highly expressed in human chondrosarcoma and promotes drug resistance in chondrosarcoma cells in vitro. *BMC Cancer* 2011;11:120.
43. Jiang LB, Liu XQ, Li B, et al. Heat shock proteins and survivin: relationship and effects on proliferation index of retinoblastoma cells. *Histol Histopathol* 2008;23:827-31.
44. Sasaki T, Lopes MB, Hankins GR, Helm GA. Expression of survivin, an inhibitor of apoptosis protein, in tumors of the nervous system. *Acta Neuropathol* 2002;104:105-9.
45. Rousseau A, Kujas M, Bergemer-Fouquet AM, van Effenterre R, Hauw JJ. Survivin expression in ganglioglioma. *J Neurooncol* 2006;77:153-9.
46. Eto M, Kodama S, Uemura N, Suzuki M. Antibody responses to survivin and their clinical significance in patients with head and neck cancer. *Head Neck* 2007;29:1128-35.
47. Wu YK, Chen KT, Kuo YB, Huang YS, Chan EC. Quantitative detection of survivin in malignant pleural effusion for the diagnosis and prognosis of lung cancer. *Cancer Lett* 2009;273:331-5.
48. Ziaee SA, Moula SJ, Hosseini Moghaddam SM, Eskandar-Shiri D. Diagnosis of bladder cancer by urine survivin, an inhibitor of apoptosis: a preliminary report. *Urol J* 2006;3:150-53.
49. Wang ZN, Xu HM, Jiang L, Zhou X, Lu C, Zhang X. Expression of survivin mRNA in peritoneal lavage fluid from patients with gastric carcinoma. *Chin Med J* 2004;117:1210-17.
50. Wang J, Huang C, Wei XY, et al. Changes of activated circulating endothelial cells and survivin in patients with non-small cell lung cancer after anti-angiogenesis therapy. *Chin Med J* 2008;121:2234-40.
51. Hoffmann AC, Warnecke-Eberz U, Liebke T, et al. Survivin mRNA in peripheral blood is frequently detected and significantly decreased following resection of gastrointestinal cancers. *J Surg Oncol* 2007;95:51-4.
52. Guney N, Soyidine HO, Derin D, et al. Serum and urine survivin levels in breast cancer. *Med Oncol* 2006;23:335-40.
53. Shehata HH, Abou Ghalia AH, Elsayed EK, Ziko OO, Mohamed SS. Detection of survivin protein in aqueous humor and serum of retinoblastoma patients and its clinical significance. *Clinical Biochemistry* 2010;43:362-6.

54. Li YH, Hu CF, Shao Q, et al. Elevated expressions of survivin and VEGF protein are strong independent predictors of survival in advanced nasopharyngeal carcinoma. *J Transl Med* 2008;6:1.
55. Xiang XJ, He YJ, Li YH, Huang H, Xu F. Clinical significance of survivin expression in peripheral T-cell lymphoma. *Ai Zheng* 2006;25:758-61.
56. Cruz-Merino LD, Henaó-Carrasco F, García-Manrique T. Role of transforming growth factor B in cancer microenvironment. *Clin Transl Oncol* 2009;11:715-20.
57. Kimchi A, Wang XF, Weinberg RA, Cheifetz S, Massagué J. Absence of TGF-beta receptors and growth inhibitory responses in retinoblastoma cells. *Science* 1988;240:196-9.
58. Horie K, Yamashita H, Mogi A, Takenoshita S, Miyazono K. Lack of transforming growth factor-beta type II receptor expression in human retinoblastoma cells. *J Cell Physiol* 1998;175:305-13.
59. Tsai JF, Chuang LY, Jeng JE, et al. Clinical relevance of transforming growth factor-beta 1 in the urine of patients with hepatocellular carcinoma. *Medicine (Baltimore)* 1997;76:213-26.
60. Helmy A, Hammam OA, El Lathy TR, Wishahi MM. The role of TGF-beta 1 protein and TGF-beta-R-1 receptor in immune escape mechanism in bladder cancer. *Med Gen Med* 2007;9:34.
61. Shim KS, Kim KH, Han WS, Park EB. Elevated serum levels of transforming growth factor-beta 1 in patients with colorectal carcinoma: its association with tumor progression and its significant decrease after curative surgical resection. *Cancer* 1999;85:554-61.
62. Chen HW, Chang YC, Lai YL, et al. Change of plasma transforming growth factor-beta1 levels in nasopharyngeal carcinoma patients treated with concurrent chemo-radiotherapy. *Jpn J Clin Oncol* 2005;35:427-32.
63. Sheen-Chen SM, Chen HS, Sheen CW, Eng HL, Chen WJ. Serum levels of transforming growth factor-beta1 in patients with breast cancer. *Arch Surg* 2001;136:937-40.
64. Shariat SF, Lotan Y, Saboorian H, et al. Survivin expression is associated with features of biologically aggressive prostate carcinoma. *Cancer* 2004;100:751-7.
65. Ikeguchi M, Iwamoto A, Taniguchi K, Katano K, Hirooka Y. The gene expression level of transforming growth factor-beta (TGF-beta) as a biological prognostic marker of hepatocellular carcinoma. *J Exp Clin Cancer Res* 2005;24:415-21.
66. Yang S, Chen H, Zhang W, Liu D, Fan E, Li Y. Expression and significance of TGF-beta1 and HSP70 in human laryngeal squamous cell carcinoma. *Lin Chuang Er Bi Yan Hou Tou Jing Wai Ke Za Zhi* 2007;21:531-4.
67. Ananiev J, Gulubova M, Tchernev G, et al. Relation between transforming growth factor-B1 expression, its receptor and clinicopathological factors and survival in HER2-negative gastric cancers. *Wien Klin Wochenschr* 2011;123:668-73.
68. Wang ST, Liu JJ, Wang CZ, et al. Expression and correlation of Lewis y antigen and TGF-B1 in ovarian epithelial carcinoma. *Oncol Rep* 2012;27:1065-71.
69. Rohatgi AK, Singh R, Shukla PK. Lactate dehydrogenase (LDH) Activity in retinoblastoma. *Indian J Ophthalmol* 1983;31:548-9.
70. Jakobiec FA, Abramson D, Scher R. Increased aqueous lactate dehydrogenase in Coats disease. *Am J Ophthalmol* 1978;85:686-9.
71. Lifshitz T, Tessler Z, Maor E, Yassar Y. Increased aqueous lactic dehydrogenase in Coat's disease. *Ann Ophthalmol* 1987;19:116-19.
72. Piro PA Jr, Abramson DH, Ellsworth RM, Kitchin D. Aqueous humor lactate dehydrogenase in retinoblastoma patients. Clinicopathologic correlations. *Arch Ophthalmol* 1978;96:1823-5.
73. Dayal Y, Goyal JL, Jaffery NF, Agarwal HC. Lactate dehydrogenase levels in aqueous humor and serum in retinoblastoma. *Jpn J Ophthalmol* 1985;29:417-22.